




THE UNIVERSITY OF
AUCKLAND
Te Whare Wānanga o Tamaki Makaurau
NEW ZEALAND

2016 - 2017

Department of Ophthalmology

Ophthalmology and Eye Disease

Overview of 4th and 5th year course



School of Medicine
Faculty of Medical and Health Sciences

TABLE OF CONTENTS

	Page No.
Lecture Timetable	1
Overview of the 4 th and 5 th Year Course	2
Lecture 1: Applied Clinical Anatomy and Physiology	3
Lecture 2: Ocular Pharmacology	7
Lecture 3: Symptoms of Eye Disease	12
Lecture 4: Signs of Eye Disease	15
Lecture 5: The Acute Red Eye	17
Lecture 6: Ocular Trauma	25
Lecture 7: Diabetic Eye Disease	34
Lecture 8: Vision Loss	45
The Auckland Eye Manual App	48

Additional Notes

Practical Skills 1: Assessing the visual apparatus	49
Practical Skills 2: Assessing visual fields and Pupillary responses	50
Practical Skills 3: Extra-ocular muscle movement and Cover test	54

Appendix – 5th Year Lecture Material

Appendix 1: Signs and Symptoms of Eye Disease	56
Appendix 2: Vision Loss - Additional Notes	59
Appendix 3: Care of the Visually Disabled	63

4th Year Teaching 2016

Lecture Timetable

Course Co-ordinators: Dipika Patel & Charles McGhee

Venue: 505-011

2 sessions: 4 hours in total

1. Thursday 30th June 8.30 – 10.30am

8.30 – 8.35am	Introduction	Professor Charles McGhee
8.35 – 9.00am	Applied Clinical Anatomy & Physiology	Dr Bia Kim
9.00 – 9.25am	Ocular Pharmacology	Dr Ilva Rupenthal
9.35 – 10.00am	Symptoms of Eye Disease	Dr James McKelvie
10.00 – 10.25am	Signs of Eye Disease	Assoc. Prof Dipika Patel

2. Thursday 30th June 11.00 – 1.00pm

11.00 – 11.25am	Acute Red Eye	Assoc. Prof Jennifer Craig
11.25 – 11.50am	Ocular Trauma	Professor Charles McGhee
12.00 – 12.25pm	Diabetic Eye Disease	Dr Stuti Misra
12.25 – 12.50pm	Vision Loss	Dr Andrea Vincent

OPHTHALMOLOGY and EYE DISEASE

Overview of 4th and 5th year course

Outline

The ophthalmology course comprises one day of lectures in 4th year and 7 days of clinical exposure / tutorials in 5th year, which should provide the student with an overview of ocular disease and its manifestations in relation to basic science and other clinical subjects, in addition to establishing core skills. Material taught in fourth year will be built upon in fifth year; acquisition of the relevant knowledge will be assumed and not repeated in fifth year.

The fourth year course will be examined at the end of the semester.

The core objectives are

1. Review and reinforce pre-clinical knowledge applicable to eye disease
2. Appreciation of key ocular symptoms and signs and underlying pathogenesis
3. Key clinical problems encountered in as an RMO/General Practitioner.
4. Appreciation of the ocular manifestations of systemic disease e.g. diabetes mellitus
5. Knowledge of the important causes of blindness in New Zealand and worldwide
6. Establish relevance of key elements of pathology, microbiology and immunology
7. An appreciation of the impact of visual disability on the patient's lifestyle, family and community
8. Basic ocular therapeutics
9. To establish core clinical skills in the assessment of patients with disorders of the visual system.

Core clinical skills to be acquired:

- A. Taking an appropriate ophthalmic history
- B. Assessment of visual acuity (near, distance, colour)
- C. Assessment of visual field to confrontation / central field by Amsler grid
- D. Examination of the anterior segment - conjunctivae, cornea, iris and pupil
- E. Pupillary examination - near, light, consensual, swinging light test
- F. Examination of the red reflex by ophthalmoscope
- G. Examination of the posterior segment using the ophthalmoscope
- H. Assess presence of squint, corneal reflexes, cover test and eye movements
- I. Basic elements of slit-lamp examination

Key patient presentations to be considered:

1. **The acute red eye**
2. **Sudden visual loss and visual impairment**
3. **The squinting child**
4. **Ocular trauma with visual impairment**

**LECTURE 1: Applied Clinical Anatomy & Physiology –
Dr Bia Kim**

Lecture 1 : Anatomy of the eye

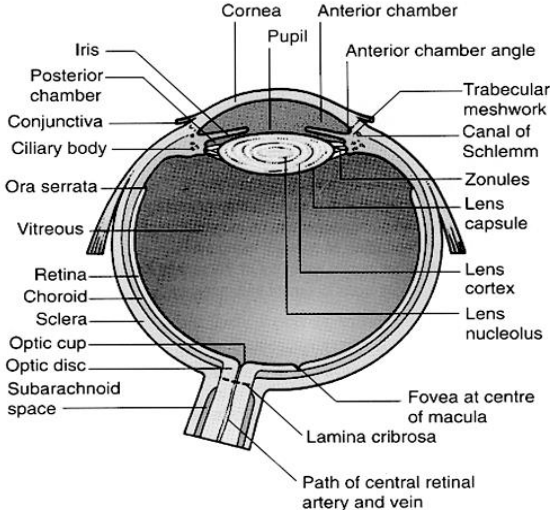


Fig. 1 Sagittal section of the eye.

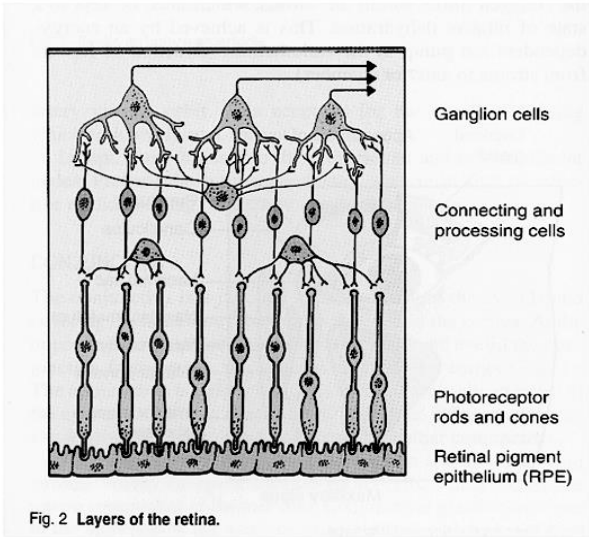


Fig. 2 Layers of the retina.

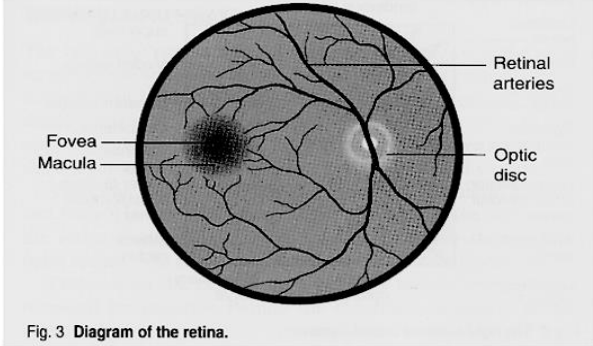


Fig. 3 Diagram of the retina.

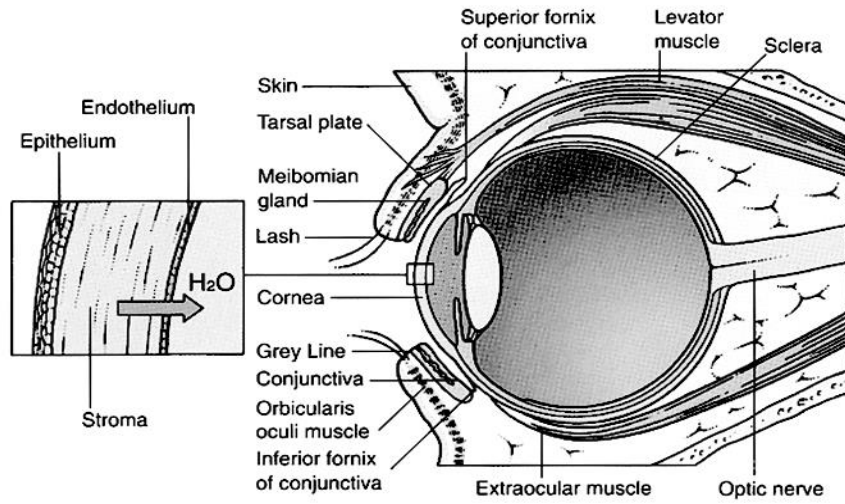


Fig. 4 Eyelids and eyeball in sagittal section.

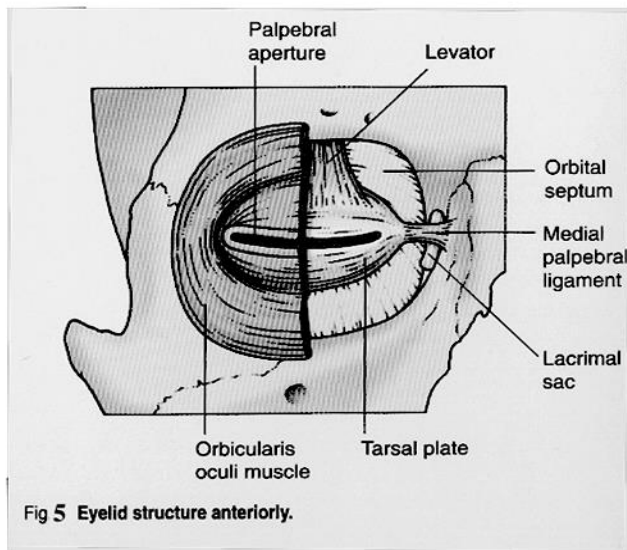


Fig 5 Eyelid structure anteriorly.

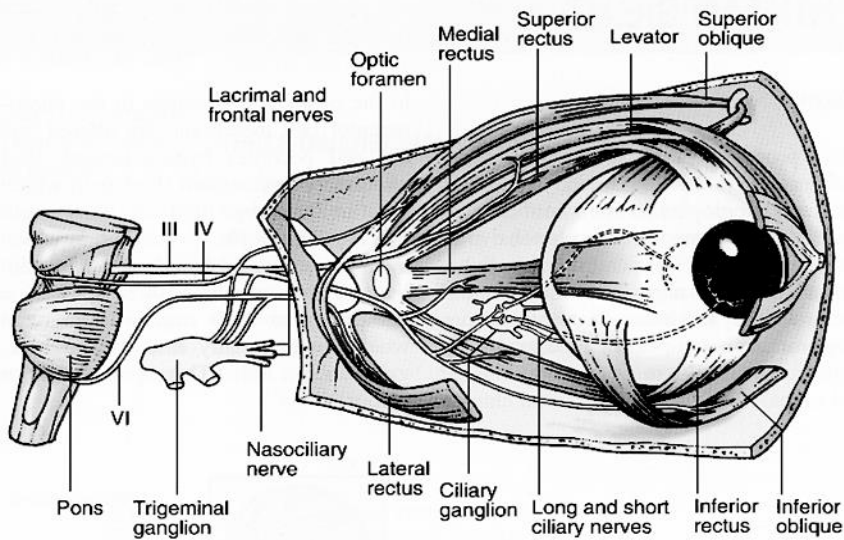


Fig. 6 The nerves and muscles of the orbit.

Lecture 1 (cont'd)

Anatomy and Physiology of the Eye

Overview of the major functions associated with ocular structures.

- 1) **Tears:** lubrication, oxygen transmission, clarity of vision, immunological protection.
- 2) **Conjunctiva:** smooth surface between eyelids and cornea, oxygen transmission, tear production, tear film adherent, defence, protection and integrity against micro-organisms and infection.
- 3) **Eyelids:** protection, tear film production and distribution, tear flow and drainage.
- 4) **Cornea:** refractive surface of fixed power, clarity, protection against micro-organisms, transparent smooth surface, oxygen transmission, ocular rigidity.
- 5) **Sclera:** protection, ocular rigidity, opaque, attachment of extra-ocular muscles.
- 6) **Lens:** refractive surface of variable power, accommodative mechanism, smooth interface with aqueous, transparency.
- 7) **Iris/Pupil:** restriction of light to retina (variable aperture), reduction of light scatter within the eye.
- 8) **Ciliary body/ ciliary epithelium:** accommodation, attachment of lens, production of aqueous humour (nutrient supply to lens and cornea and waste metabolite removal from globe),
- 9) **Choroid:** provides oxygen and nutrition to outer retina.
- 10) **Vitreous chamber:** vitreous humour maintains ocular shape, protection of ocular structures during trauma.
- 11) **Retina:** provides visual sensation and conversion of light images into nerve impulses. Supported by the retinal pigment epithelium, which is a layer of cells external to the retina essential for the formation of photopigments, the renewal of photoreceptors, the reduction of damage due to scattered light and the transportation of water and nutrients to the retina.
- 12) **Optic nerve:** transmits electrical signals to the brain via the optic nerve, optic chiasm, optic radiation, lateral geniculate nucleus and occipital cortex for further processing of the visual image.

Retinal physiology

The electromagnetic spectrum humans are visually responsive to is *light* between 400-700nm.

The functioning of rods and cones differs under scotopic (low light) versus photopic (daylight) light levels, location within the visual field, retinal location as well as stimulus size and position.

When a photon collides with the retina it is transmitted through the *inverted retina* to the photoreceptors where *photochemical transduction* results in the conversion of the light signal to an electrical signal.

Rods and cones

Rods and cones process the visual signal in characteristic ways and are described by performance functions which include the *rod and cone spectral sensitivity curves* as well as *light and dark adaptation curves* among other measures. They also differ in the *minimum detectable number of photons* required for visual processing as well as their ability to process signals across visual space and over time; namely their *spatial and temporal summation*.

Rods are more suited to processing the signals within visual images seen at low light levels (twilight, scotopic conditions) while cones process visual images seen at higher levels of luminance (bright daylight, photopic conditions).

Cones are responsible for the detection of colour and fine details (visual acuity) and are more concentrated in the central visual field. Rods are responsible for the detection of peripheral movement.

Visual Performance

Perceptual stimulus response functions therefore provide an understanding of visual dysfunction and may be used to indicate and facilitate earlier detection of ocular disease and refractive errors.

Form/Spatial Vision: clinically measured by visual acuity which varies with contrast, brightness, eccentricity and the testing procedure. Reflects the rod/cone distributions.

Colour Vision: hue, saturation, brightness and colour interactions are indicative of cone function and the associated processing of the visual signal. Colour vision testing may therefore provide indications for early detection of disease (i.e. saturation testing; blue/yellow vs. red/green defects).

Binocular Vision: associated with central vision. Requires clear images from both eyes, co-ordinated eye movements and intact cortical fusion mechanisms.

NOTES:

Lecture 2: Ocular Pharmacology

Dr Ilva Rupenthal



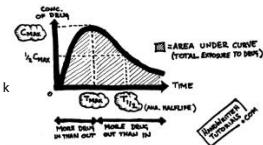
Ocular Pharmacology – An Introduction

Dr Ilva Rupenthal
 Senior Lecturer and Director of the Buchanan Ocular Therapeutics Unit
 Department of Ophthalmology
 Faculty of Medical and Health Sciences
 The University of Auckland
 i.rupenthal@auckland.ac.nz

Pharmacokinetics vs. Pharmacodynamics

Pharmacokinetics: What the body does to the drug

- ADME: Absorption
 Distribution
 Metabolism
 Elimination
- Parameters: C_{max} , t_{max} , $t_{1/2}$, AUC, k

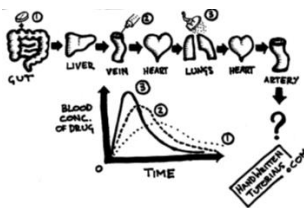


- Pharmacodynamics: What the drug does to the body
- Pharmacological effect → This will be covered in detail in 5th year



Absorption

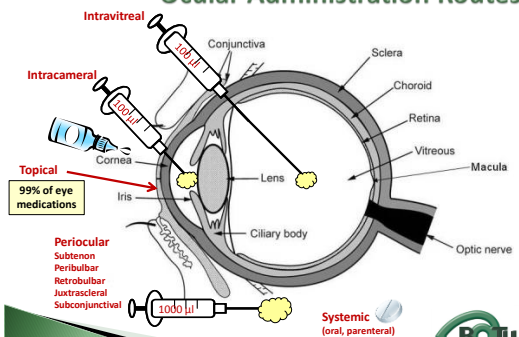
How the drug gets into the eye...



- Route of administration
 - topical
 - intracameral
 - intraocular
 - periocular
 - systemic
- Membrane properties (cornea)
- Drug characteristics (pKa, logP and MW)
- Dosage form



Ocular Administration Routes

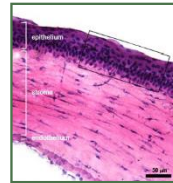


Topical Ocular Drug Delivery

- ⊕ Ease of application
- ⊕ Direct application to target site
- ⊕ Smaller drug dose required
- ⊕ Rapid onset of action
- ⊗ Contamination of drops
- ⊗ Need for preservative → local toxicity
- ⊗ Limited penetration (A) and fast elimination (E)
- ⊗ Systemic absorption → side effects



Membrane Properties - Cornea



- ▶ Cornea as important mechanical barrier
- ▶ Main pathway for ocular penetration
- ▶ **Sandwich-like structure**
- ▶ Only drugs with MW <5kDa and logP of 10-100 can pass
- ▶ Thickness may affect drug permeation



- Epithelium - lipophilic
- Stroma - hydrophilic
- Endothelium - lipophilic



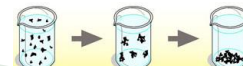
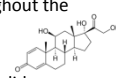
Dosage Forms - Solutions

- ▶ **homogeneous mixture composed of only one phase**
- ▶ solute (drug) is dissolved in solvent (buffer)
- ▶ account for >90% of ophthalmic formulations
- ▶ β-blockers, PGA, α-agonists, CAI, some AB
- The Auckland Eye Manual p. 329-332
- ⊕ good stability
- ⊕ easy to prepare
- ⊕ low cost
- ⊗ **fast drainage** → limited residence time
- ⊗ low drug permeability through cornea
- ⊗ drug **bioavailability** generally <10%



Dosage Forms - Suspensions

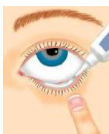- ▶ **heterogeneous mixture composed of two phases**
- ▶ internal solid phase (drug) is dispersed throughout the external liquid phase (buffer)
- ▶ steroids (Pred Forte, Maxidex, Flucon)
- The Auckland Eye Manual p. 331
- ⊕ reduced drainage as particles remain in lower lid
- ⊕ prolonged residence time → higher drug **bioavailability**
- ⊗ high cost, sterilisation may cause physical instability
- ⊗ particle size <10 μm → foreign body sensation → tearing
- ⊗ particle aggregation/sedimentation
- **MUST** be shaken before use





Dosage Forms - Ointments

- ▶ semisolid preparation intended for external application
- ▶ drug in hydrocarbon base (no water!)
- ▶ Chloramphenicol and Acyclovir The Auckland Eye Manual p. 332
- ⊕ high viscosity → reduced drainage → better absorption → higher bioavailability
- ⊕ no stinging upon application
- ⊕ oily base →
 - no dilution by tears
 - no preservative required
 - suitable for moisture sensitive drugs
 - lubricating nature
- ⊕ blurred vision → application only at night time
- ⊕ greasy → discomfort/irritation → reflex tearing



Distribution

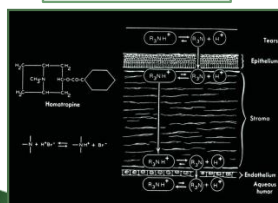
How the drug moves around the eye...

Henderson-Hasselbalch

$$pH = pK_a - \log \frac{[\text{unionised}]}{[\text{ionised}]}$$

Drug characteristics (pKa, logP, MW)

Drug-protein binding in tear fluid



pK_a (homatropine) = 9.7

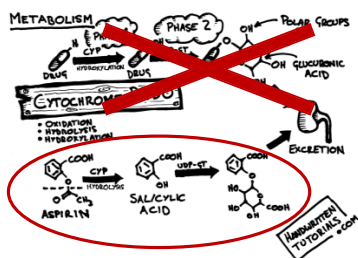
@ pH 7: ≥ 99% of drug in unionised form (lipophilic) → can penetrate lipophilic epithelium

@ > pH 7 → more ionised drug → easily diffuses through hydrophilic stroma



Metabolism

How the drug is broken down...

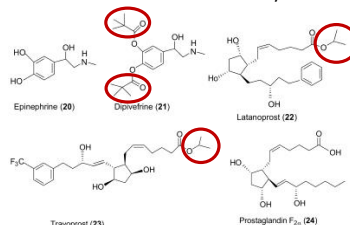


- ▶ ~~First Pass~~
- ▶ Enzyme induction/inhibition
- ▶ Drug activation



Metabolism – Drug Activation

- ▶ Ester prodrugs → more lipophilic → better absorption/penetration into cornea → activation by esterases

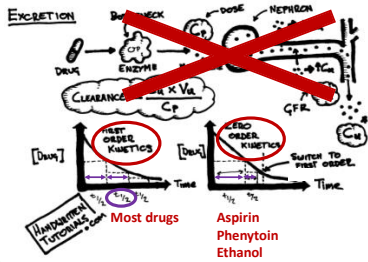


Chowdhury P, Borah BM. 2012. Soft Glucocorticoids: Eye-Targeted Chemical Delivery Systems (CDSs) and Retrometabolic Drug Design. A Review. ed.: INTECH Open Access Publisher



Elimination

How fast the drug leaves the eye...

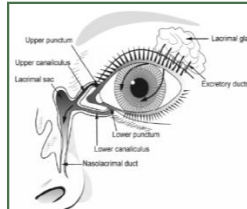


➤ **Nasolacrimal drainage**

➤ Kinetics
 ◦ First order
 ◦ Zero order



Elimination – Nasolacrimal Drainage



- Normal tear volume: 7-10 μ l
- Lower lid can hold: < 30 μ l
- Eye dropper delivers: 40-70 μ l
- Tear fluid turnover doubles after eye drop application → **washout**
- **Reflex tearing** due to irritation (pH, foreign body sensation)
- > 80% of drug leaves via nasolacrimal duct
- High surface area and blood supply in nose → **systemic absorption**
 → side effects (β -blockers, steroids)



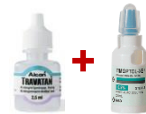Correct Eye Drop Application

- **Shake bottle** before use (suspensions!)
- Apply **one drop** into lower lid pocket
- **Close eyes** and **obstruct duct**
 - **Normal blinking** → <10% of drug remains after 5 min
 - **Closed eyes** → >50% of drug remains after 5 min
 - **Nasolacrimal obstruction** → >80% of drug remains after 5 min
 → higher **absorption** across cornea
- Leave **5 min** between drops (washout effect)



Second Drop Washout Effect

- Second drop washout effect
- If drug A is followed by drug B
 - @ 30 sec: 50% of drug A is washed out
 - @ 120 sec: 17%
 - @ 5 min: 5%



- Leave **5 min** between drops
- Less washout → higher **absorption**
- Combination rather than separate drops

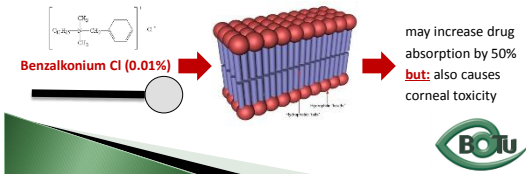


Generic Bioequivalence


Is one eye drop the same as another?

Two drops of the same drug may not be bioequivalent:


- pH of formulation → drug ionisation → solubility/permeation
- Particle size of drug in suspension → drainage/solubility
- Addition of preservatives → corneal permeation/absorption



10 things you need to know

1. Shake bottle before use → suspensions!
 2. Apply only one drop → drainage ↓ side effects ↓
 3. Close eyes and obstruct duct → drainage ↓ absorption ↑
 4. Leave 5 min between drops → washout ↓ absorption ↑
 5. Two eye drops of the same drug concentration may not be bioequivalent → absorption & elimination → efficacy & side effects
- 


10 things you need to know

6. Topically applied drops can cause systemic side effects → β-blockers, steroids
 7. Preservatives can cause ocular toxicity and allergies
 8. Ointments and suspensions exhibit longer drug action than drops → drainage ↓ absorption ↑
 9. Use ointments only at night time → blurred vision
 10. Corneal conditions may influence drug absorption → membrane properties
- 

THANK YOU



Any questions or feedback email l.rupenthal@auckland.ac.nz



LECTURE 3: Symptoms of Eye Disease –

Dr James McKelvie

(Further notes on Signs & Symptoms can be found in Appendix 1)

History

A careful history will:

- Suggest the disease & its cause
- Direct your clinical examination
- Direct your investigations
- Place the problem in the context of the patient and their circumstances

as a whole and allow you to plan their management.

Standard format: Presenting complaint and Symptom characteristics

Vision loss

- Sudden or gradual
- Constant vs. Intermittent- duration
- Extent of visual loss: blur vs. complete blackout
- Part of the field involved
- Associated symptoms e.g. headache, haloes

Red eye

- Unilateral / bilateral
- Associated symptoms
 - Pain
 - Vision affected
 - Discharge

Pain

- Character of the pain: sharp vs. dull
- Onset
- Exacerbating or relieving factors
- Associated symptoms e.g haloes or blurred vision
- Past ocular history e.g trauma, shingles
- Systemic enquiry, consider referred pain

Photophobia = light sensitivity

Usually due to

- keratitis or
- uveitis

Double vision

- Onset e.g after head injury
- Associated symptoms e.g headache or blurred vision
- Past history e.g of squint
- Systemic enquiry e.g diabetic, myasthenia
- Two distinct images are seen: horizontal or vertical displacement relative to each other
- May be monocular or binocular
- Where are they relative to each other?

Flashes & Floaters

- Flashes originate from stimulation of the neurosensory retina by traction from the vitreous
- Floaters due to degeneration of the vitreous
- Sudden onset suggests a posterior vitreous detachment.
- Large red floaters or a drop in vision suggest vitreous haemorrhage
- Could suggest retinal detachment when severe eg. Shower of floaters, many flashers, accompanied by a “black curtain” over part of the visual field in one eye.

Past Ocular History

- Spectacle wear
 - Myope
 - hypermetropia - presbyopia
- Contact lens wear
- Squint or amblyopia
- Surgery or trauma

Past Medical History

- Vascular history if acute visual loss
- Rheumatological history in patients with uveitis
- Diabetes
- PMR

Medications & Allergies

- Give you an idea of the patient's general state of health
- Remember systemic medications have ocular effects
- Ocular medications have systemic effects

Family History

Ocular

- Glaucoma
- Squint
- Cataract
- Poor vision
- Age Related Macular Degeneration
- Retinal Detachment

Social History

- Smoking / Diet
- Occupation- implications of visual disease
- Living situation- e.g elderly and lives alone.

NOTES:

LECTURE 4: Signs of Eye Disease

Assoc. Prof Dipika Patel

(Further notes on Signs & Symptoms can be found in Appendix 1)

Examination of the eye consists of Visual Acuity & Slit Lamp

Visual acuity

- Unaided
- Pinhole
- Glasses if available
- Near vision

Slit Lamp Examination

- Inspect the structures of the eye from anterior to posterior

Fluorescein Drops

- Stains epithelial defects
- Assessing tear film
- Detecting leaks
- Checking intraocular pressure

Intraocular pressure

- IOP Assessment – goldman tonometry

Fundus examination

- **Must** dilate pupils: Tropicamide eye drops

Colour vision

- Ishihara plates

Visual fields

- Test on confrontation, preferably with a red target

Red Reflex

Extraocular muscles

Pupil reactions

- Responses to light
 - Direct
 - Consensual
- RAPD
- Response to accommodation

Case Study: Down Syndrome

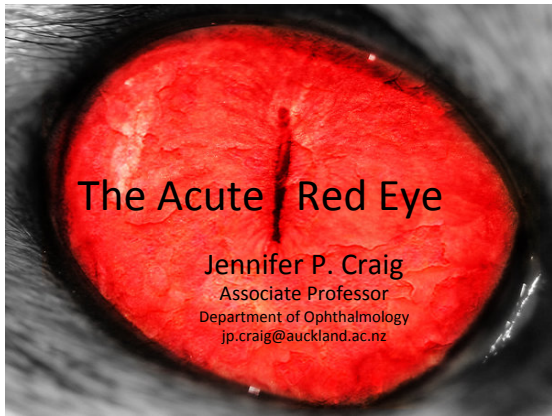
- Epicanthal folds
- Up-sloping palpebral fissures
- Iris Brushfield Spots
- Blepharitis
- Epiphoria Congenital naso-lacrimal duct obstruction
- Strabismus
- Keratoconus
- Cataract
- Refractive Problems



NOTES:

Lecture 5: The Acute Red Eye

Assoc. Professor Jennifer Craig

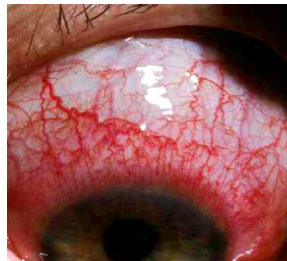

Confident Assessment and Management



Question 1 – acute red eye

- 34 year old male
- Eye 'a bit sore'
- Sensitive to light
- Vision slightly blurry

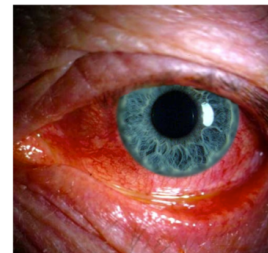

Sight threatening or self limiting?



Question 2 – acute red eye

- 78 year old female
- Sore (uncomfortable) since this morning
- Couldn't open eyes easily first thing
- Intermittent blurring of vision

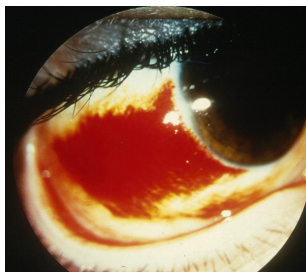


Sight threatening or self limiting?



Question 3 – acute red eye

- 29 year old male
- Concerned about red eye that appeared suddenly
- Not painful



Sight threatening or self limiting?



Sight threatening or self limiting?

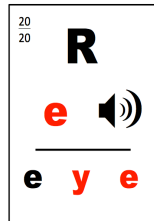


For Ophthalmic History and Ophthalmic Examination tips see Auckland Eye Manual pages 1 - 18



Acute Red Eye Differential Diagnosis

- Conjunctivitis
- Keratitis
- Uveitis/Iritis
- Acute Angle Closure Glaucoma
- Anterior Scleritis
- Episcleritis
- Subconjunctival Haemorrhage
- Ocular Trauma

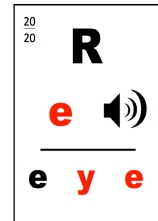


For Acute Red Eye Flow Chart, see Auckland Eye Manual: pages 19-20



Acute Red Eye Differential Diagnosis

- Conjunctivitis
- Keratitis
- Uveitis/Iritis
- Acute Angle Closure Glaucoma
- Anterior Scleritis
- Episcleritis
- Subconjunctival Haemorrhage
- Ocular Trauma



For Acute Red Eye Flow Chart, see Auckland Eye Manual: pages 19-20



Conjunctivitis

History	Signs
Past ocular disease ≈	Vision X
Vision X	Discharge ✓
Pain and severity X	Redness and distribution: Bulbar and palpebral
Photophobia X	Corneal clarity X
Ocular discharge ✓	Pupil size and mobility X
Systemic symptoms ≈	Intraocular pressure X

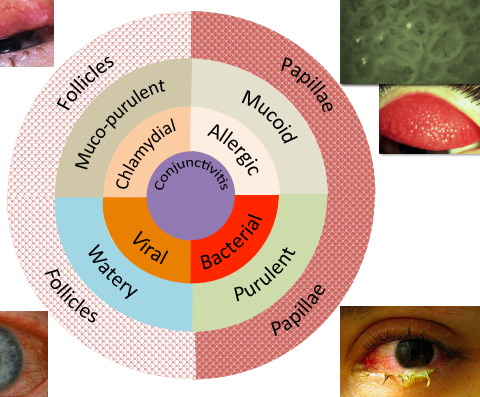
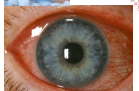
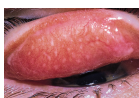
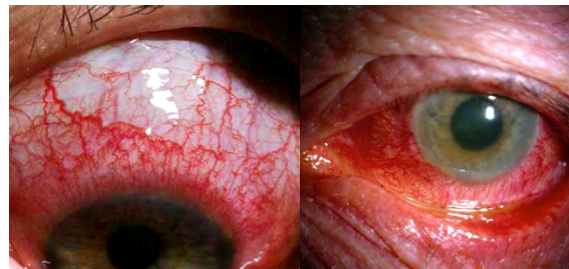
For Ophthalmic History and Ophthalmic Examination tips see Auckland Eye Manual pages 1 - 18
For Conjunctivitis, refer to Auckland Eye Manual: pages 75 - 84



Distribution of redness

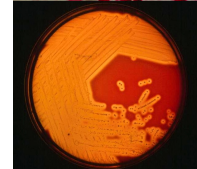
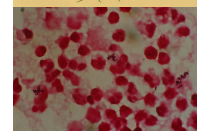
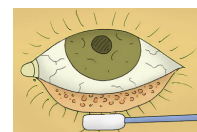
Circum-corneal / ciliary

Bulbar / palpebral



Conjunctivitis: Management

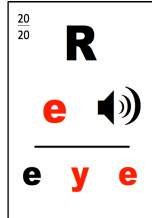
- Largely self-limiting
- Swab and identify responsible organism
 - Bacterial
 - Chloramphenicol
 - Fucithalamic
 - Viral
 - No specific treatment
 - Chlamydial
 - Systemic tetracycline





Acute Red Eye Differential Diagnosis

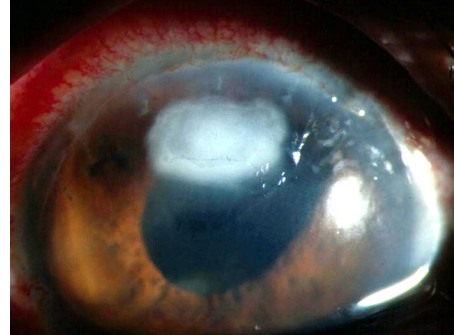
- Conjunctivitis
- Keratitis
- Uveitis/Iritis
- Acute Angle Closure Glaucoma
- Anterior Scleritis
- Episcleritis
- Subconjunctival Haemorrhage
- Ocular Trauma



For Acute Red Eye Flow Chart, see Auckland Eye Manual: pages 19-20



Keratitis



Keratitis

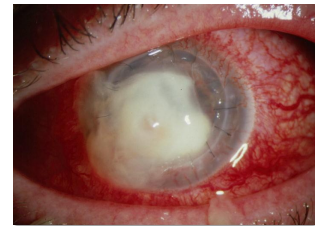
History	Signs
Past ocular disease ≈	Vision ↓
Vision ↓	Discharge ✗
Pain and severity: ++ to +++	Redness and distribution: Ciliary
Photophobia ✓	Corneal clarity ↓
Ocular discharge ✗	Pupil size and mobility ✗
Systemic symptoms ✗	Intraocular pressure ✗

For Ophthalmic History and Ophthalmic Examination tips see Auckland Eye Manual pages 1 - 18
For Keratitis, refer to Auckland Eye Manual: pages 93 - 102

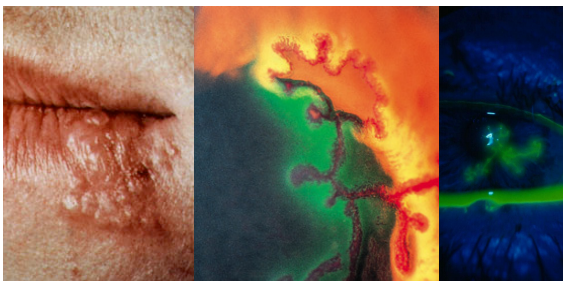

Microbial keratitis

- Bacterial
- Viral
- Fungal
- Acanthamoeba
(contact lenses)



Viral keratitis: Herpes Simplex Virus



Keratitis: Management

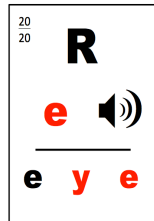
- Corneal scrape
- Mydriatic
- Start intensive antimicrobials immediately
- Bacterial
 - Monotherapy: ciprofloxacin
 - Dual therapy: fortified Kefzol & Tobrex
- HSV
 - Acyclovir ointment 5x daily





Acute Red Eye Differential Diagnosis

- Conjunctivitis
- Keratitis
- Uveitis/Iritis
- Acute Angle Closure Glaucoma
- Anterior Scleritis
- Episcleritis
- Subconjunctival Haemorrhage
- Ocular Trauma



For Acute Red Eye Flow Chart, see Auckland Eye Manual: pages 19-20



Anterior Uveitis

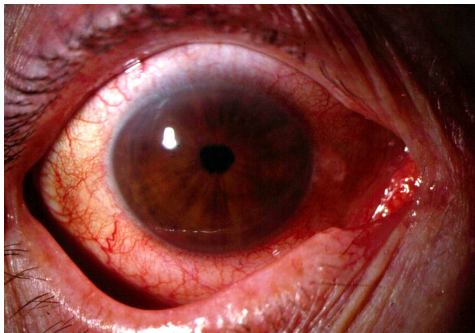
History
Past ocular disease ✗
Decreased vision ✓
Pain and severity ✓
Photophobia: +++
Ocular discharge ✗
Systemic symptoms ≈

Signs
Vision ✓
Discharge ✗
Redness and distribution: Ciliary
Corneal clarity ✗
Pupil size and mobility: Small (miotic)
Intraocular pressure ✗

For Ophthalmic History and Ophthalmic Examination tips see Auckland Eye Manual pages 1-18
For Anterior Uveitis, refer to Auckland Eye Manual: pages 151-152

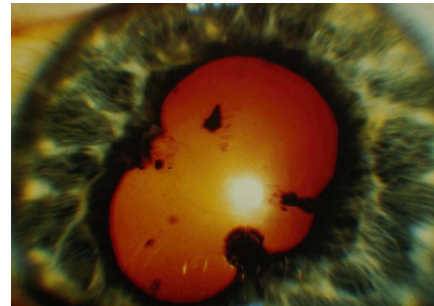


Acute Anterior Uveitis / Iritis



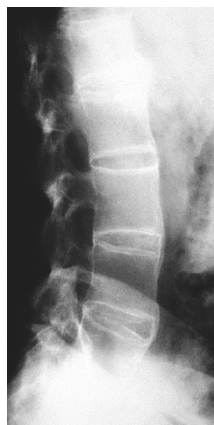Acute Anterior Uveitis/Iritis

Posterior
synechiae



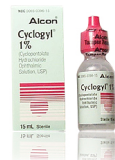Aetiology

- Idiopathic
- Ankylosing spondylitis
- Reiters syndrome
- Juvenile arthritis
- Psoriatic arthropathy
- Sarcoidosis



Anterior Uveitis: Management

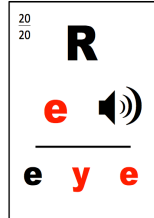
- Subdue Inflammation
 - Topical corticosteroids
- Prevent Posterior Synechiae
 - Mydriatic e.g. cyclopentolate
- Reduce IOP if elevated
 - Betablocker e.g. timolol





Acute Red Eye Differential Diagnosis

- Conjunctivitis
- Keratitis
- Uveitis/Iritis
- **Acute Angle Closure Glaucoma**
- Anterior Scleritis
- Episcleritis
- Subconjunctival Haemorrhage
- Ocular Trauma



For Acute Red Eye Flow Chart, see Auckland Eye Manual: pages 19-20



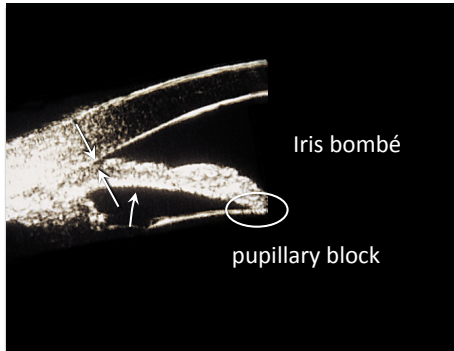
Acute Angle Closure Glaucoma

History	Signs
Past ocular disease X	Vision ↓ +++
Decreased vision: +++	Discharge X
Pain and severity: +++	Redness and distribution: Ciliary
Photophobia X	Corneal clarity ↓
Ocular discharge X	Pupil size and mobility: Fixed mid-dilated
Systemic symptoms X	Intraocular pressure ↑↑

For Ophthalmic History and Ophthalmic Examination tips see Auckland Eye Manual pages 1 - 18
For Acute Angle Closure Glaucoma, refer to Auckland Eye Manual: pages 147 - 148

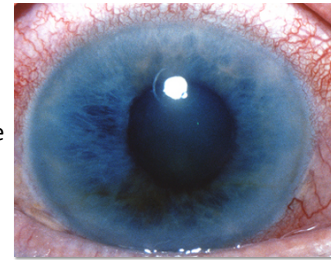


ACAG: Anatomical predisposition



Acute Angle Closure Glaucoma

- Red eye
- Hazy cornea
- Pupil mid-dilated
- Pupil non-reactive
- High IOP



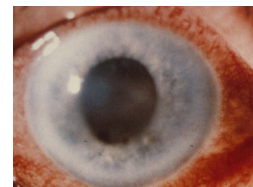
Acute Angle Closure Glaucoma

- Incidence
 - 1/1000 (Caucasian) to 1/100 (Asian) > 40 yrs
 - Ratio M:F is approximately 1:4
 - Predisposition
 - Short eye
 - Narrow angle
 - Large lens
- Therefore the older female hypermetrope is at risk



AACG: Acute Management

- Reduction of IOP (Typically > 50mmHg)
 - Topical Agents
 - Prostaglandin analogues
 - Betablockers
 - Alpha agonists
 - Systemic Agents
 - Acetazolamide
 - Mannitol

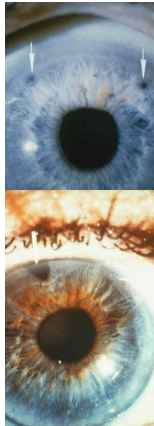




AACG: Surgical management

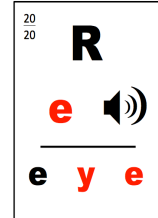
Aim: to re-establish normal aqueous flow & maintain IOP reduction

- YAG laser iridotomy
- Crystalline lens extraction
- Surgical iridectomy
- Trabeculectomy



Acute Red Eye Differential Diagnosis

- Conjunctivitis
- Keratitis
- Uveitis/iritis
- Acute Angle Closure Glaucoma
- Anterior Scleritis
- Episcleritis
- Subconjunctival Haemorrhage
- Ocular Trauma

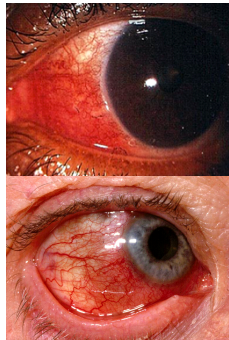


For Acute Red Eye Flow Chart, see Auckland Eye Manual: pages 19-20



Anterior Scleritis

- Relatively rare
- Very severe boring pain
- Focal injection of sclera
- Can lead to blindness if untreated
- Associated with systemic disease



Anterior Scleritis

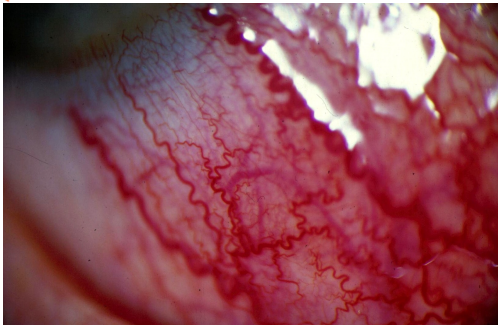
History
Past ocular disease ≈
Vision ✗
Pain and severity: +++
Photophobia ✗
Ocular discharge ✗
Systemic symptoms ✓

Signs
Vision ✗
Discharge ✗
Redness and distribution: Sectorial, bluish
Corneal clarity ✗
Pupil size and mobility ✗
Intraocular pressure ✗

For Ophthalmic History and Ophthalmic Examination tips see Auckland Eye Manual pages 1 - 18
For Anterior Scleritis, refer to Auckland Eye Manual: pages 127 - 128

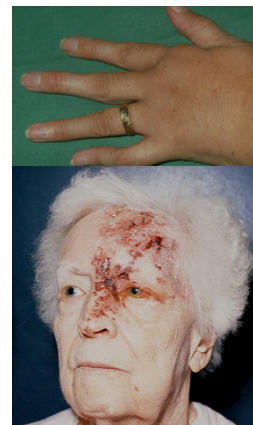

Anterior Scleritis



Anterior Scleritis: Systemic associations

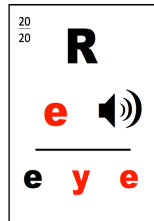
- Rheumatoid arthritis
- Herpes Zoster Ophthalmicus





Acute Red Eye Differential Diagnosis

- Conjunctivitis
- Keratitis
- Uveitis/iritis
- Acute Angle Closure Glaucoma
- Anterior Scleritis
- Episcleritis
- Subconjunctival Haemorrhage
- Ocular Trauma

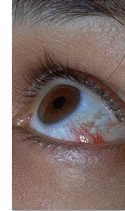

For Acute Red Eye Flow Chart, see Auckland Eye Manual: pages 19-20

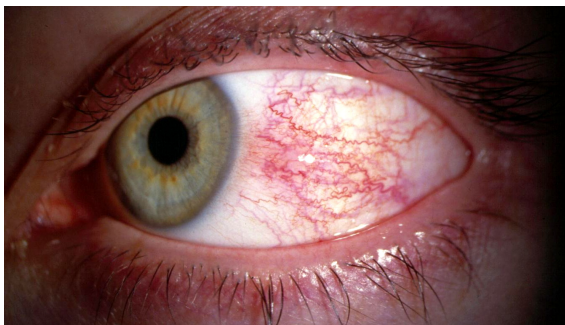


Episcleritis

- Relatively common
- Mild ocular discomfort
- Mild superficial injection
- Usually requires no treatment
- Seldom associated systemic disease



Episcleritis



Episcleritis

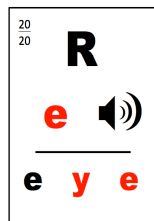
History	Signs
Past ocular disease ≈	Vision X
Vision X	Discharge X
Pain and severity: +	Redness and distribution: Sectorial, pink
Photophobia X	Corneal clarity X
Ocular discharge X	Pupil size and mobility X
Systemic symptoms X	Intraocular pressure X

For Ophthalmic History and Ophthalmic Examination tips see Auckland Eye Manual pages 1 - 18
For Episcleritis, refer to Auckland Eye Manual: pages 125 - 126



Acute Red Eye Differential Diagnosis

- Conjunctivitis
- Keratitis
- Uveitis/iritis
- Acute Angle Closure Glaucoma
- Anterior Scleritis
- Episcleritis
- Subconjunctival Haemorrhage
- Ocular Trauma

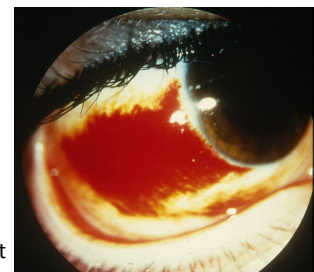


For Acute Red Eye Flow Chart, see Auckland Eye Manual: pages 19-20



Subconjunctival Haemorrhage

- Focal bleeding under conjunctiva
- Severe coughing
- Valsalva manoeuvre
- Rarely systemic hypertension
- Requires no treatment





Subconjunctival haemorrhage

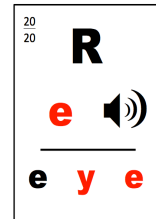
History	Signs
Past ocular disease X	Vision X
Vision X	Discharge X
Pain and severity X	Redness and distribution: Opaque red
Photophobia X	Corneal clarity X
Ocular discharge X	Pupil size and mobility X
Systemic symptoms X	Intraocular pressure X

For Ophthalmic History and Ophthalmic Examination tips see Auckland Eye Manual pages 1-18
For Subconjunctival Haemorrhage, refer to Auckland Eye Manual: pages 19-20; image (post-trauma) page 41



Acute Red Eye Differential Diagnosis

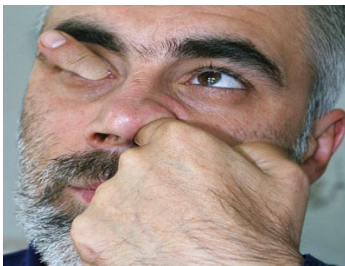- Conjunctivitis
- Keratitis
- Uveitis/iritis
- Acute Angle Closure Glaucoma
- Anterior Scleritis
- Episcleritis
- Subconjunctival Haemorrhage
- Ocular Trauma



For Acute Red Eye Flow Chart, see Auckland Eye Manual: pages 19-20



Ocular trauma!!



Beware of picking your nose

For Trauma, refer to Auckland Eye Manual: pages 35-49



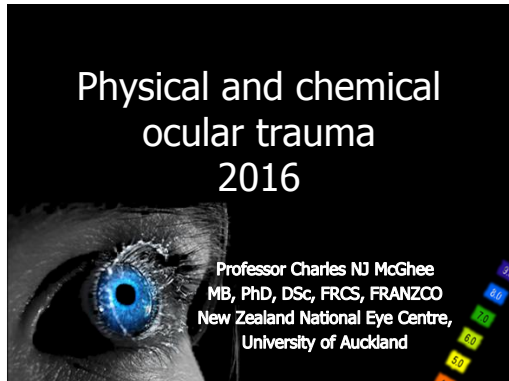
The Acute Red Eye

- A systematic examination will enable appropriate management / referral decisions to be made.



LECTURE 6: Ocular Trauma

Professor Charles McGhee



Epidemiology of eye trauma

- Eye injury admissions: 15.2 per 100,000
- Penetrating injuries: 3.6 per 100,000
- 40% of monocular blindness is traumatic
- Two thirds are male
- Majority are of working age

Causes and mechanisms



Assessment of eye trauma

- Rule out life threatening injuries
- Treat chemical injuries
- Rule out globe threatening injuries
- Examine both eyes and lids
- Consider radiological imaging
- Plan management

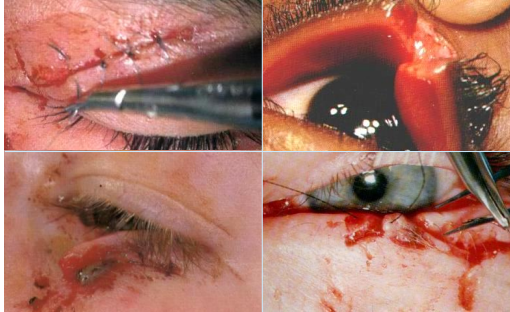Establish mechanism



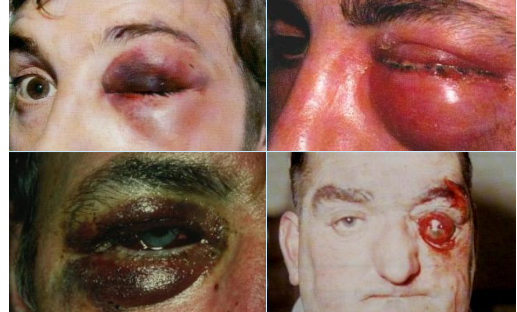Ocular history

- Visual symptoms
 - Visual acuity, floaters, pain
- Past ocular history
- Previous injuries or ocular surgery
- Past medical history

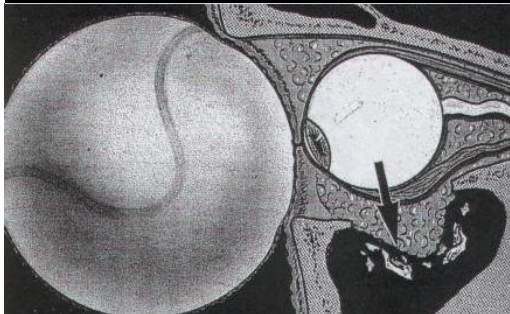
Eyelid injuries



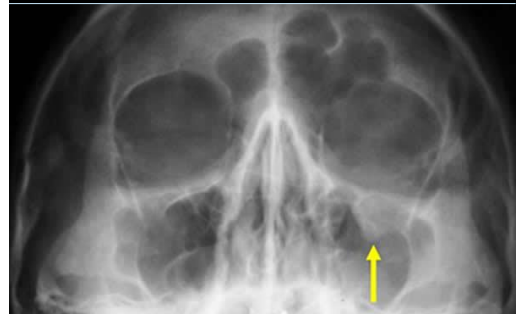
Haemorrhage



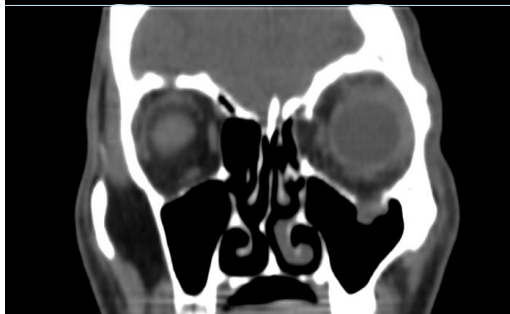Orbital blow out fracture



Orbital blow out fracture

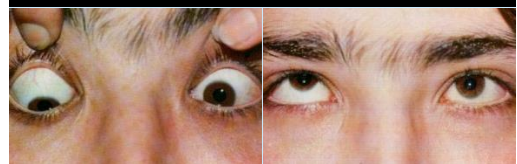

Orbital blow out fracture

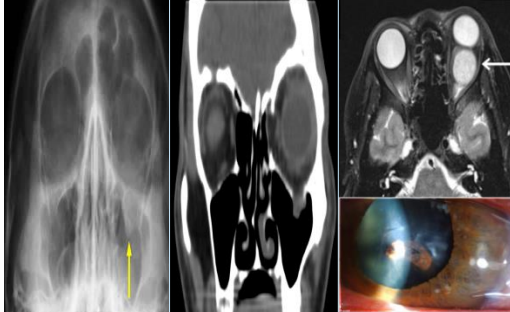


Orbital blow out fracture - signs

- Black eye (haematoma)
- Infra-orbital nerve anaesthesia
- Double vision (upgaze & downgaze)

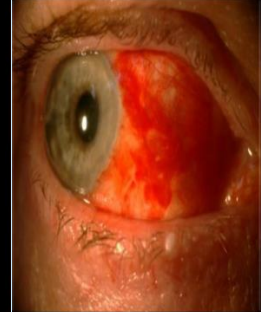

Radiological imaging



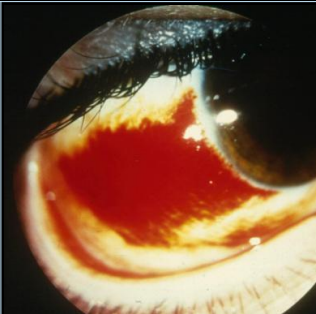
Globe injury

- Sub-conjunctival haemorrhage
- Corneal abrasion
- Foreign body
- Blunt ocular trauma
- Penetrating injury

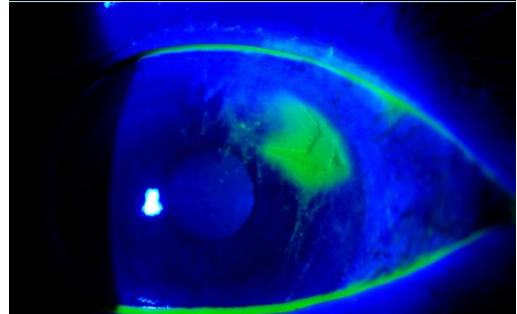


Subconjunctival haemorrhage

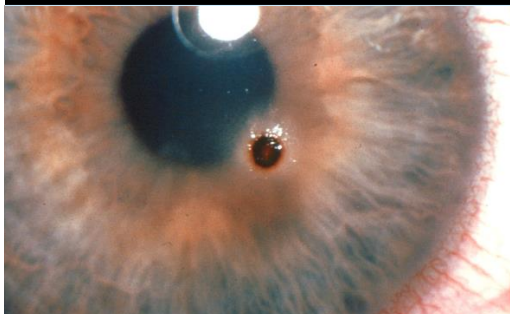
- Coughing
- Vomiting
- Trauma
- Raised BP



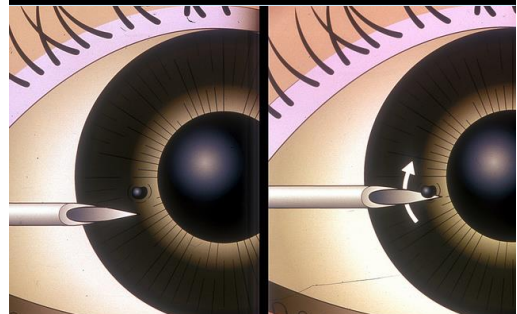
Corneal abrasion



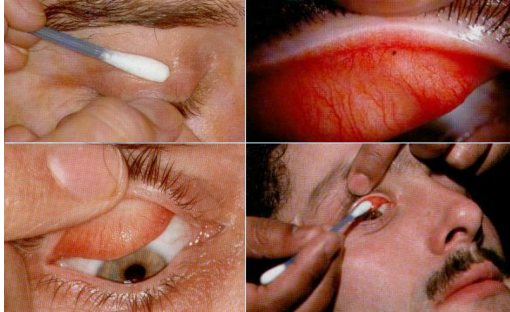
Corneal foreign body



Corneal foreign body



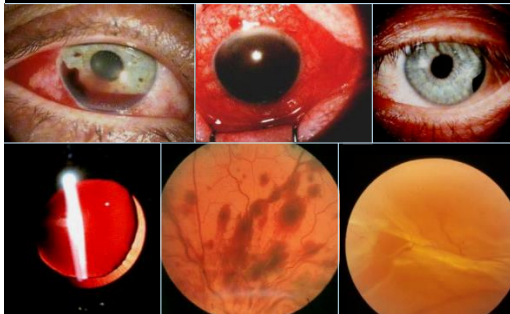Corneal foreign body



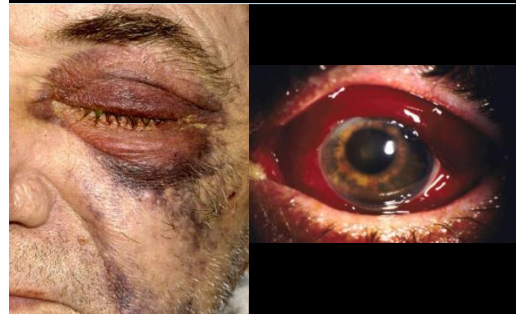Blunt trauma to globe



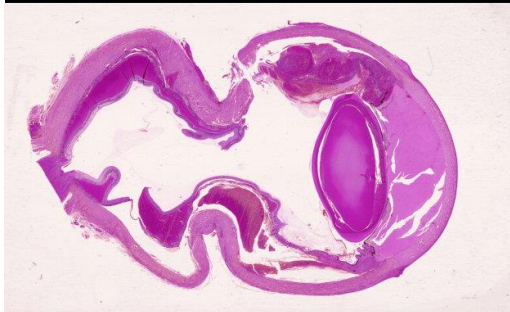Blunt trauma to globe



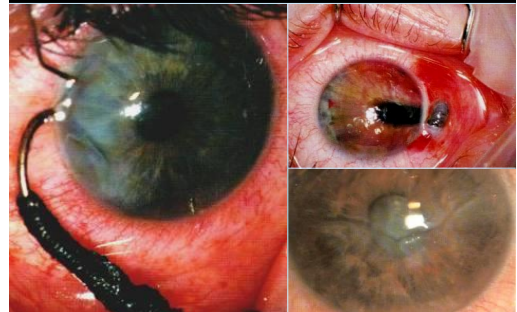Blunt trauma to globe



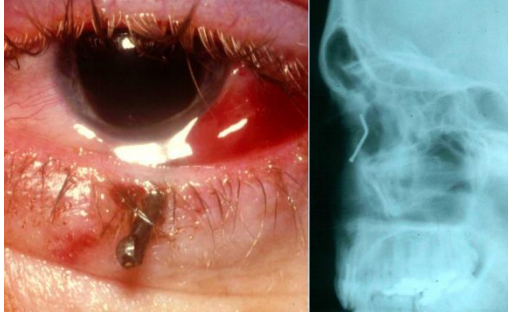
Blunt trauma to globe



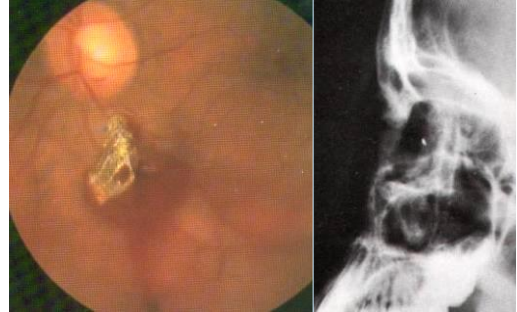
Penetrating eye injury



Penetrating eye injury




Penetrating eye injury



Aetiology of chemical injuries

- **Industrial**
 - Alkali's & acids
 - High pressure & temperature
- **Farming**
 - Ammonia in fertilizers
- **Home**
 - Cleaning agents
- **Assault**
 - Alkali & acids

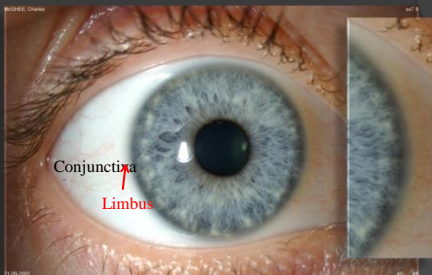

Epidemiology of chemical injuries

- **USA**
 - Assault No 1 cause of alkali injuries
 - <10% industrial injuries chemical
- **Croyden Eye Unit UK**
 - 221 chemical injuries
 - 89% accidental (63% at work)
 - Only 11% assaults
 - ~50% alkali, males (76%) 16-25 yrs

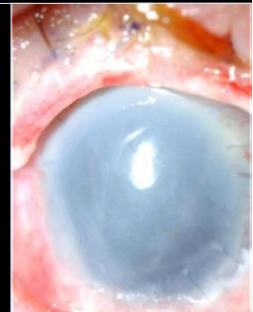

Remember normal anatomy



Chemical injury

- Alkalis
- Acids
- High pressure
- High temperature
- Particulate matter



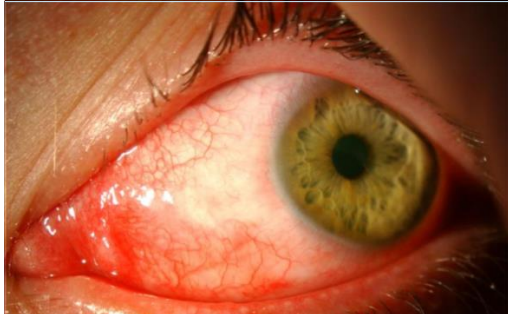Alkalis



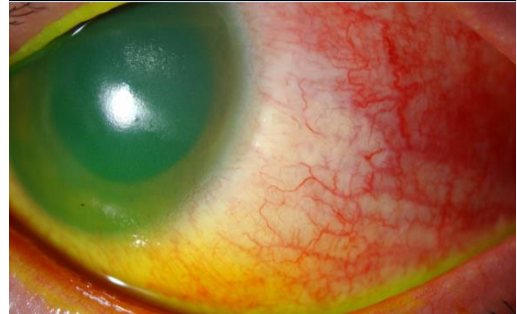Acids



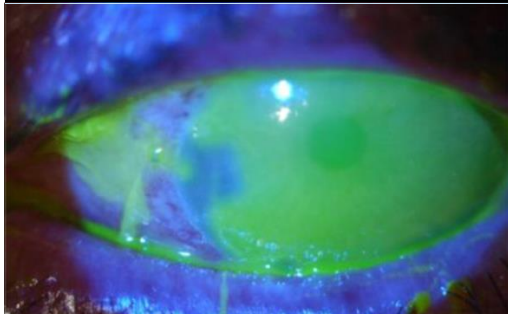
Chemical injury



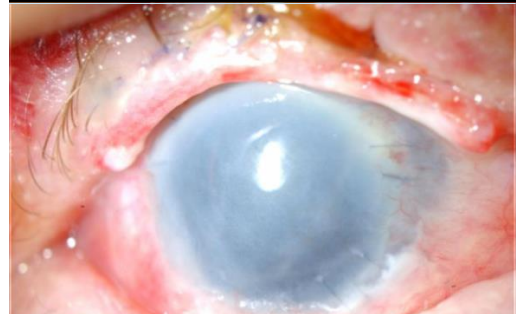Chemical injury



Chemical injury



Chemical injury



Chemical injury: alkalis



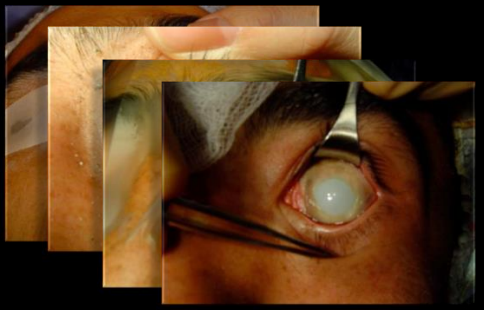- **Ammonium**
 - Ammonium ions penetrate instantaneously
- **NaOH (Na Hydroxide, caustic soda, lye)**
 - Hydroxyl ions take 3-5 minutes
 - Typically appears in drain cleaner
- **Ca(OH)₂ (Ca Hydrate, Lime, Quicklime)**
 - Plaster, mortar, cement
 - Particulate nature prolongs exposure
- **All penetrate rapidly through the cornea & anterior chamber causing saponification and cell death**

Chemical injury: acids



- **Weak acids**
 - Precipitate proteins within the corneal and conjunctival epithelium creating a partial barrier to further ingress
- **Strong acids**
 - Overcome layer of protein precipitation and enter anterior chamber with results indistinguishable from strong alkali burns

Chemical injury



Safety glasses!



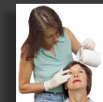Eye Chemical Injuries 101

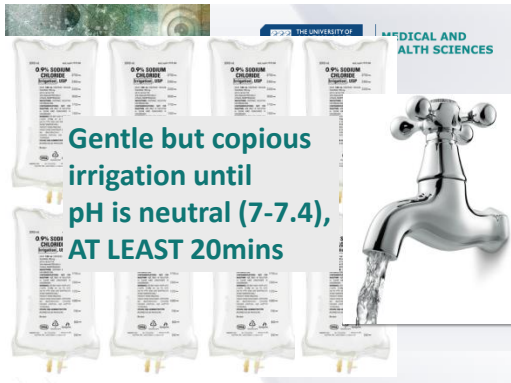RULE 1

In chemical injuries irrigate, irrigate, irrigate *before* taking full history or performing ocular examination!

Emergency Treatment: irrigation

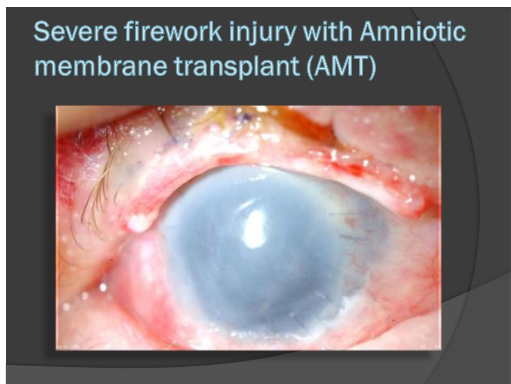
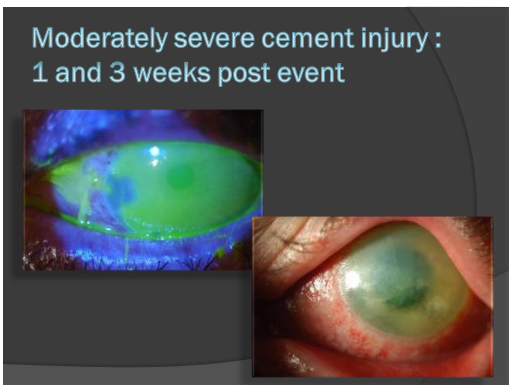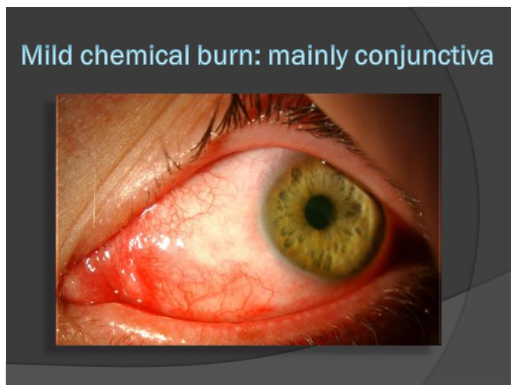
- **Immediate management**
 - Copious irrigation at scene of incident
 - Ongoing irrigation for 1-2 hours
 - **SINGLE MOST USEFUL Rx**
 - **Use any neutral fluid available**





Eye Chemical Injuries 101


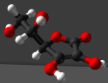
RULE 2
 Remove all particulate matter as soon as possible to avoid ongoing chemical injury



- Medium term medical Rx**
- ⦿ G. preservative free antibiotic
 - ⦿ G. preservative free prednisone**
 - ⦿ G. atropine 1% 1-2 per day
 - ⦿ G. ascorbate 10% 2 hourly
 - ⦿ G. citrate 10% 2 hourly
 - ⦿ Oral ascorbate 2G daily
 - ⦿ Oral analgesia for mod/severe pain
 - ⦿ Consider systemic doxycycline 100mg BD

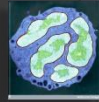
Vitamin C (ascorbate)

- Vital to collagen Synthesis
- Ascorbate depleted from cornea by severe Alkali or Acid injuries
- Scorbutic cornea prone to lysis
- Oral and topical ascorbate reduces risk of perforation



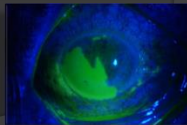
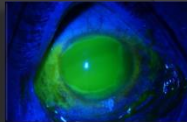
Citrate (Citric Acid)

- Powerful chelation agent for calcium
- Depletes calcium from PMN plasma membrane
- Reduction in calcium reduces 2nd wave of PMN extravasation from vessels
- Reduces PMN related inflammation
- Works in concert with Ascorbate



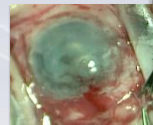
Prednisolone in chemical injuries

- Preservative free topical prednisone phosphate 0.5%
- Suppress inflammation in initial post-injury week
- May contribute to delayed healing and corneal melting after 7-10 days



Surgical rehabilitation

- Symblepharolysis
- Cicatricial entropion/ectropion repair
- Debridement of epithelium
- Amniotic membrane transplant
- Limbal stem cell transplant
- Keratoprosthesis

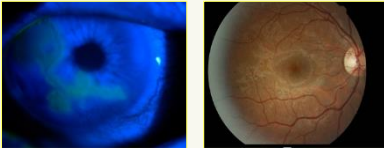


Conclusions

LECTURE 7: Diabetic Eye Disease

Dr Stuti Misra

Diabetic Eye Disease



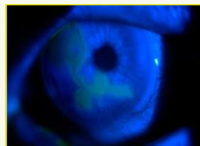
Dr Stuti Misra, BOptom, PhD, FFAO
Department of Ophthalmology
University of Auckland
s.misra@auckland.ac.nz

Organs affected

- Large blood vessel disease
 - Heart
 - Nervous system
 - Peripheral vascular disease
- Small blood vessel disease
 - **Eyes**
 - Kidneys
 - Nervous system

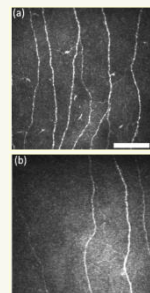
Ocular surface: Tear film and Cornea

- Tear film - Dry eye
 - Reduced tear quantity
 - Reduced tear film stability
- Reduced corneal sensitivity
- Greater risk of viral and fungal infections



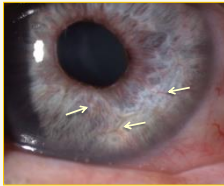
Cornea

- Corneal nerve damage
- Keratopathy
 - Superficial punctate keratitis
 - Recurrent corneal erosions
 - Persistent epithelial defects



Iris, Pupil and Crystalline lens

- Miotic Pupil
- Iris neovascularisation
- Lenticular induced myopic shift!
- Cataract (post-subcapsular)



Retina

Diabetic retinopathy

Retina

- Two main retinal diseases in the older patient
 - Diabetic retinopathy
 - Age related macular degeneration
- Can you SEE the difference?????

Retina

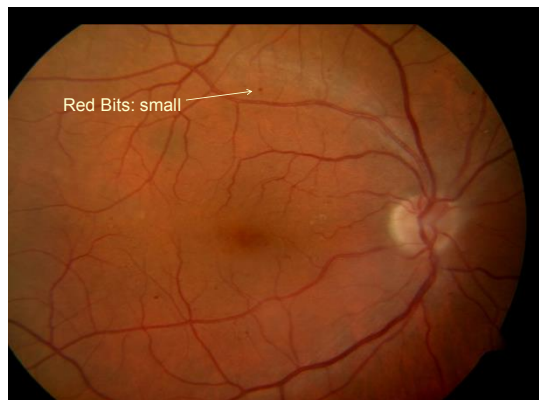
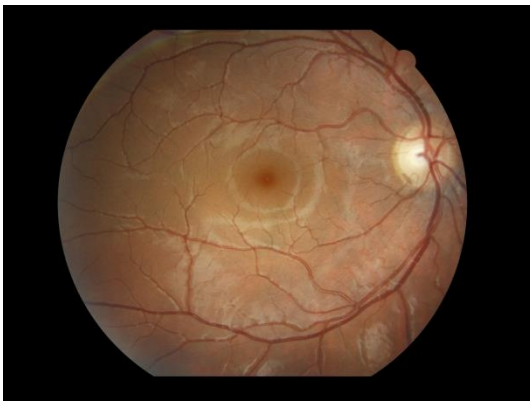- Diabetic retinopathy
 - Accounts for >90% blindness under the age of 60
- Age related macular degeneration
 - Accounts for >90% blindness over the age of 60

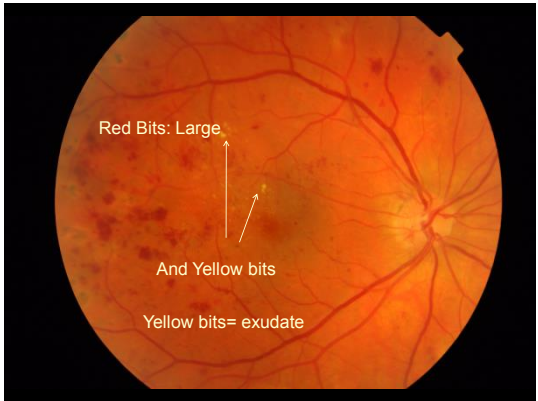
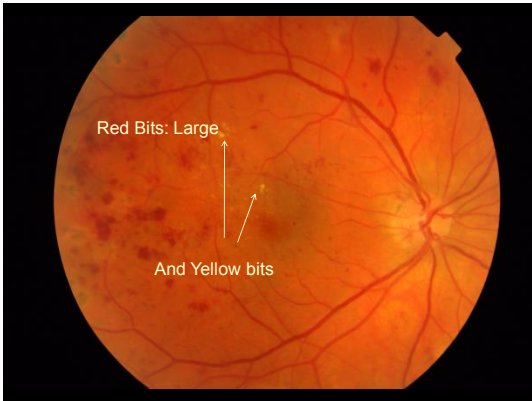
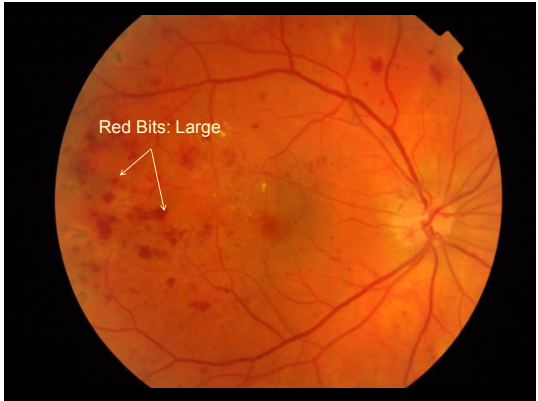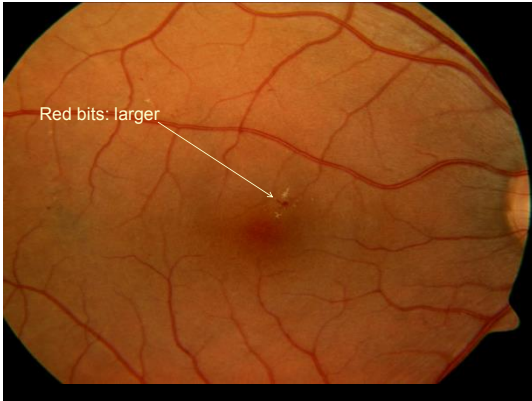
Key differential in retinal macular haemorrhages

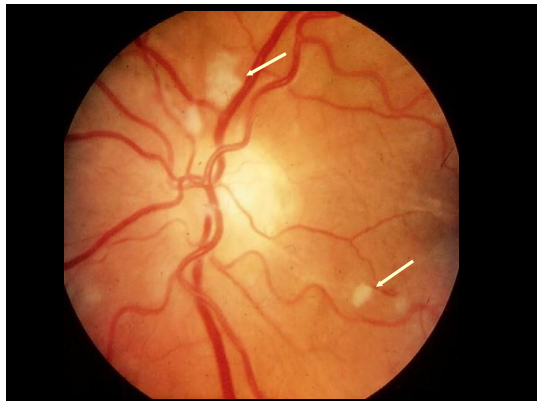
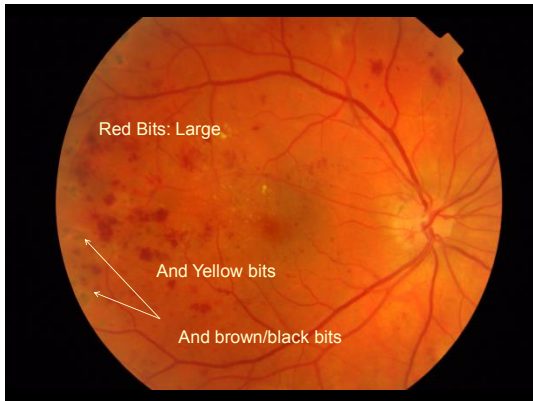
- Principally, either diabetic maculopathy* or age related macular degeneration
- Less commonly branch retinal vein occlusion*
- Differentiate can be tricky:
 - Age ARMD > 60 years
 - Age DR < 60 years
 - Diabetic maculopathy* by itself is uncommon
 - Look for retinopathy beyond macula*

Clinical features

- Red bits (small and or large)
 - Blood: microaneurysms, haemorrhages
- White/yellow bits
 - Cotton wool spots, drusen & exudate
- Brown/black bits
 - Laser, pigment







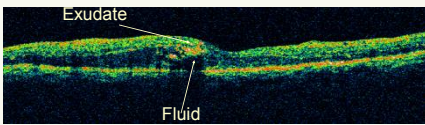
More than one vessel involved

All the retinal signs accounted for !!

- Blocked vessels lead to
 - retinal haemorrhages
 - Cotton wool spots
 - Abnormal retinal vessels
 - Venous "sausaging", irregularity
 - Intra-retinal microvascular anomalies
 - Disc new vessels
 - Retinal new vessels

All the retinal signs accounted for !!

- Leaking vessels lead to
 - Protein (hard exudate)
 - Haemorrhage
 - Fluid (diffuse and local)
 - Intra-retinal and Sub-retinal

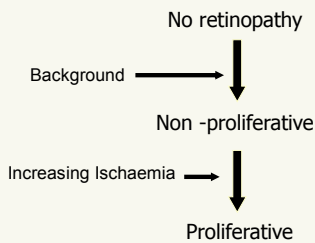


OCT scan showing fluid (oedema)

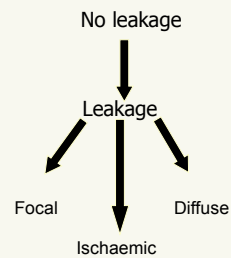
Diabetic retinopathy (DR)

- How do we classify it
- Background: bits and bobs but good vision!
- Pre-proliferative/ Proliferative: Ischaemic signs of varying degree leading to "new vessel growth"
- Maculopathy: involvement of the macula

Classification of retinopathy vessel blockage

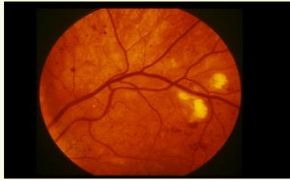

Classification of retinopathy vessel leakage

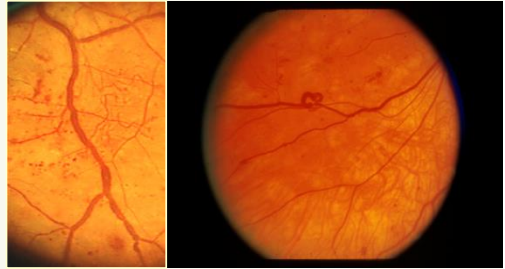

Non-proliferative Signs

- Microaneurysms
- Intraretinal haemorrhages
- Hard/Soft exudates

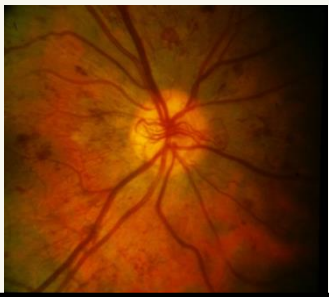

Venous changes

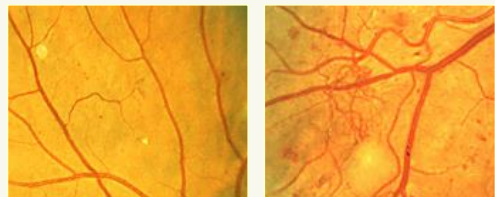


Proliferative retinopathy

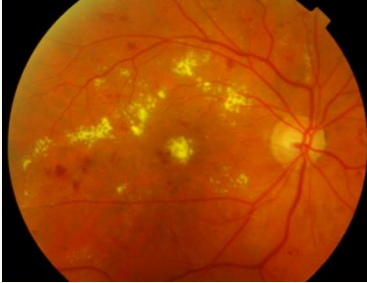- Neovascularisation



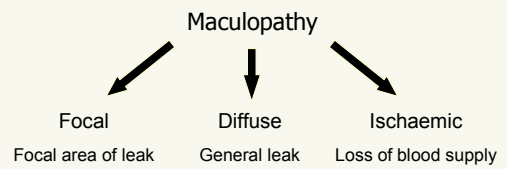
Intra-retinal microvascular abnormalities (IRMA)



Diabetic Macular oedema



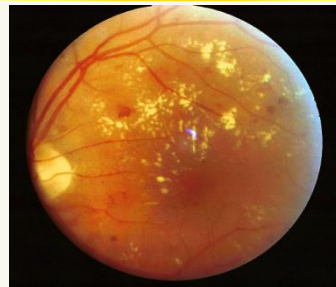Classification of maculopathy vessel leakage/blockage



Maculopathy

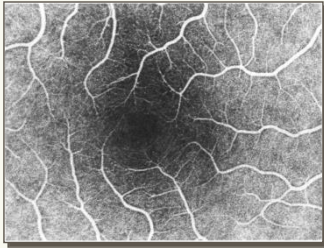
- Focal
 - Fluid, lipid and proteins leak from a focal group of microaneurysm often leaving a well defined yellow ring – ring or circinate exudate
- Ischaemic
 - Capillaries underlying the fovea are all occluded
- Diffuse
 - All the capillaries leak.

Maculopathy

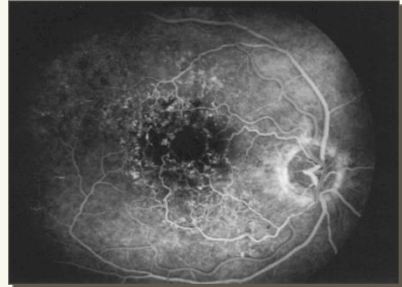

Normal vasculature

Fluorescein angiogram

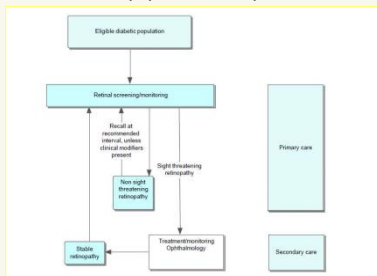


Ischaemic maculopathy




Screening Programs in NZ

- About 25% of NZ population has 'pre-diabetes'



Social Engineering

- Healthy Living
 - Exercise
 - Weight loss
 - Support groups



Expensive, difficult to measure outcomes, politically unpopular

Why should we be interested?

- Increasing numbers worldwide: 552 million by 2030
 - International Diabetes Federation
- Personal cost
 - Morbidity, reduced life expectancy etc
- Economic cost in New Zealand
 - Diabetes NZ estimated \$600 million spent in 2008
 - Projected cost for 2020 \$1.61 billion
 - Ministry of Health 2009, Report on NZ Cost-of-Illness

Why are we interested?

- Retinopathy present in 1/3rd of diabetics
- About 4-8% have retinopathy at diagnosis
- Leading cause of blindness in working age-group
- Prompt recognition and treatment of sight-threatening eye disease can prevent sight-loss

Treatment of retinopathy

- Historically no treatment
 - "diabetics died" before chronic complications developed
- Historically poor systemic treatment
 - Laser protocols for blockage e.g. pan retinal photocoagulation
 - Laser protocols for leakage e.g. focal laser
- Bevacizumab (Avastin)
 - Help reducing macular oedema and neovascularisation

General management

- Education and support
- Institute good diabetic control
- Lifestyle changes
 - Weight loss
 - Dietary modification
 - Exercise
 - Cessation of smoking
- Carbohydrate control
 - Diet
 - Oral hypoglycemics
 - Insulin
- Control BP & Lipids
- Monitor renal function
- Management of the complications of diabetes

Programmes "Get Checked" . Budget 2006 \$76m for obesity. CM "Lets Beat Diabetes"

Risk of retinopathy

- Age
- Duration of DM
- Glycaemic control
- Hypertension
- Lipid status
- Anaemia
- Pregnancy
- Obesity
- Smoking
- Alcohol use
- Other Systemic disease
- Ethnicity

Summary

- Blood and stuff in both retinae = diabetic retinopathy if pt < 60yrs
- If macula involvement = maculopathy
- If no macula involvement think "blockage"

Questions....

LECTURE 8: Vision Loss

Dr Andrea Vincent

(Further notes on the causes of vision loss can be found in Appendix 2)

Patient 1: 58 year old

(Refer Auckland Eye Manual - section 2-5 p 60)

PC: Loss of vision in his left eye

- Better in the morning, worse through the day.
- Fluctuates
- Worse when tired.
- Associated with diplopia- and then diplopia resolves and he has no vision in left eye.

Differential Diagnosis of Ptosis

- Trauma
- Orbital Cellulitis
- III Cranial Nerve Palsy
- **Myasthenia**

Patient 2: 21 year old

(Refer Auckland Eye Manual - section 3-5 p 79)

PC: Increasing difficulty seeing out of his right eye.

- Sticky discharge
- Used antibiotics without much improvement.
- Vision improves with a blink.

Patient 3: 18 year old girl

(Refer Auckland Eye Manual - section 4-1 p 93)

PC

- Sore left eye after a party.
- Red
- Poor vision
 - Light sensitive

Patient 4: 25 year old

(Refer Auckland Eye Manual - section 4-2 p 95)

PC

- Red painful left eye
- Loss of vision
- Photophobic
 - Recently under stress and quite tired

Patient 5: 27 year old

(Refer Auckland Eye Manual - section 12-1 p 249)

PC: Sudden loss of vision in left eye

- Woke one morning - put her contact lenses in and noticed she couldn't see clearly
- Developed associated pain
- No problems in the right eye

On examination:

	Right	Left
VA	6/6	6/36
Pupils		Left RAPD
Colour Vision	14/14	3/14
VF	Normal	Central defect

Fundus examination - Diagnosis?

Optic Neuritis

• Clinical features:

- Decreased VA
- Decreased Colour Perception
- Relative afferent pupillary defect
- Normal or swollen optic nerve
- Often associated with MS

Patient 6: 62 year old man

(Refer Auckland Eye Manual - section 9-3 p 185)

PC: Loss of vision

- Flashes for 1 week.
- Spiders in front of his eyes.
- Shadow in front of eye

Past Ocular History: ??

Patient 7: 57 year old man

(Refer Auckland Eye Manual - sections 9-12,13,14 p 199-202)

PC: Loss of vision

- Previous days he had loss of vision that lasted approximately 5 min in same eye.
- Sudden blackening of vision

PMH

- Smokes 40/day
- Hypertension
- Hyperlipidaemia

On examination:

	Right	Left
VA	CF only	6/6
Pupils	Right RAPD	
Colour Vision	Unable	14/14

Fundus examination - Retinal vein occlusion

Patient 8: 72 year old man

(Refer Auckland Eye Manual - section 9-11 p 197)

PC: Big sneeze- and when opened his eyes noticed flies all over his wife.

- Questions?
 - Only right eye.
 - Flies moves with his eyes.

PMH

- Diabetic- IDDM 20 years
-

Patient 9: 68 year old woman

(Refer Auckland Eye Manual - section 9-10 p 195)

- **PC: Noticed that while she was knitting her needles were bent rather than straight.**

- Gradually became worse.

Metamorphopsia: Age related macular degeneration

Gradual loss of vision -

- Age related macular degeneration
- Diabetic retinopathy
- Chronic open angle glaucoma
- Extreme myopia
- Cataract

Patient 10: 72 yr presenting with LOV left eye- down to NPL

(Refer Auckland Eye Manual - section 12-3 p 252)

One day later: now NPL in Both eyes

Clinical Challenge?

Constitutional Symptoms?

GCA-Visual loss

- **Majority have profound visual loss.**
 - 20% experience antecedent transient visual loss.
 - Bilateral involvement is common.
 - **1/3 lose vision in second eye within 2 days**
 - **1/3 within one week**
 - **1/3 within one month**

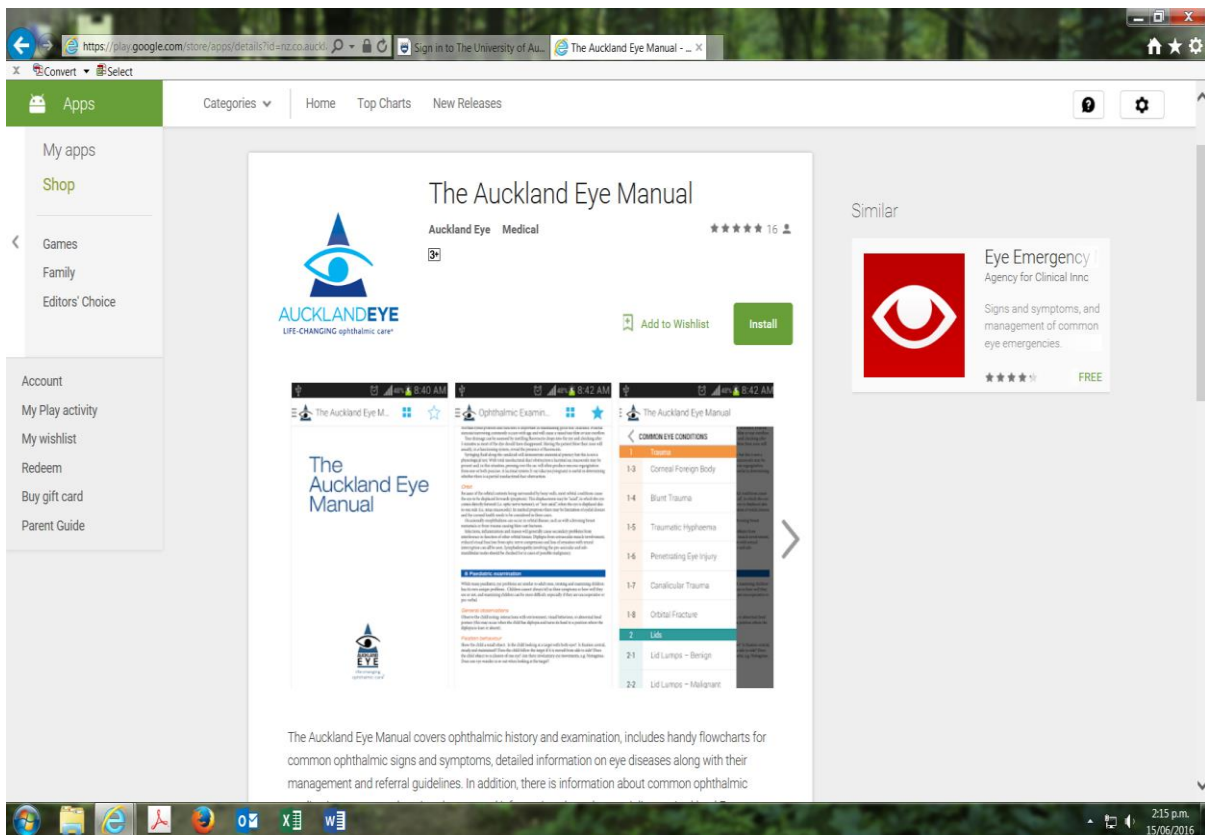
Start Treatment with *Steroids!*

Biopsy is the Gold Standard

Temporal Artery Biopsy

The Auckland Eye Manual

Available free from Google Play Store
or Apple Apps.



PRACTICAL SKILLS 1: ASSESSING THE VISUAL APPARATUS

OPHTHALMOSCOPY

Students must be familiar with the following key elements

- 1.) How to switch a standard ophthalmoscope on and off. The importance of using the lowest illumination necessary. Advantage of low room illumination where possible.
- 2.) The focusing dial: clockwise (yellow/white) for plus lenses (+1 to +20), anticlockwise (red) for minus lenses (-1 to -35). Importance of focusing - dialling in lenses compensates for both the observer's and the patient's refractive errors eg. if the observer has no refractive error and the patient is myopic, minus lenses will be required to focus on the retina.
- 3.) Observer should remove glasses unless astigmatic (and patient should remove glasses unless very, very myopic) to enable the ophthalmoscope to be held as close to the observer's eye as possible.
- 4.) Right eye, right hand, and right forefinger on dial of ophthalmoscope should be used to examine patient's R eye, and vice versa for left. Keep top of ophthalmoscope close to observer's brow such that the ophthalmoscope aperture is close to the eye.
- 5.) Patients must be given clear instructions. Ask patient to look directly ahead or slightly upward, asking patient to look at a target may be confusing since the observer may well block the target causing patient confusion and eye movement.
- 6.) Put approximately +5 into dial and observe red reflex from 20-30 cm. The red reflex will usually be brought into sharp focus by dialling the focus dial anti-clockwise.
- 7.) Stand to the side of the patient, place hand on patient's forehead (or shoulder) and whilst keeping pupil aligned move closer to eye from a slightly temporal approach. Dial lenses to bring retina into focus.
- 8.) The patient's pupil is like a keyhole, the nearer you are the more you see, the observer should bring the ophthalmoscope very close to the patient's eye (3-5cm) whilst keeping it close to their own. The importance of pupil dilatation (g. tropicamide) will be noted from lecture and practicals (fifth year).
- 9.) Magnification is approximately x15 and the first object encountered is usually the optic disc which will fill much of the undilated view. If the optic disc is not visualised the vessels should be followed to the disc, remembering that the "V" created by the branching of vessels always points to the disc.
- 10.) Students should follow a methodical pattern of examination. A six point fundal examination routine should be followed: a) disc b) superior temporal arcade vessels and retina c) inferior temporal arcade vessels and retina d) inferior nasal arcade vessels and retina e) superior nasal arcade vessels and nasal retina f) macula. Always ask the subject to look in the direction of the portion of retina you are examining ie look up for superior retina, look left for nasal aspect of right retina etc.

PRACTICAL SKILLS 2: ASSESSING VISUAL FIELD AND PUPILLARY RESPONSES

Aim - Learn to test and understand the fields of vision and pupil reflexes.

Both can be taught in minutes, done in seconds, and should from now on be part of the routine comprehensive student examination of any patient e.g. on admission to a medical ward, accident and emergency etc.

ASSESSING PUPIL REFLEXES

LIGHT REFLEX: Review and understand, using available diagrams, that the pupillary light reflex consists of a four neurones reflex arc:

1st neurone: Connects the photoreceptors in retina with the pre-tectal nucleus in the midbrain at the level of the superior colliculus. Decussate in chiasm.

2nd neurone: Connects pretectal nucleus to both the ipsilateral and contralateral Edinger Westphal nuclei, this is why a unilateral light response evokes bilateral and symmetrical pupillary constriction.

3rd neurone: Connects the Edinger Westphal nuclei to the ciliary ganglion. In the orbit, the parasympathetic fibres pass in the inferior division of the **third nerve** to reach the ciliary ganglion. (only parasympathetic fibres synapse here)

4th neurone: Leaves the ciliary ganglion and passes with the short ciliary nerves to innervate the sphincter pupillae.

NEAR REFLEX:

Remember the **near triad** 1) increased accommodation 2) convergence of the visual axes 3) constriction of the pupils. The term light-near dissociation identifies a condition where the light reflex is absent or abnormal but the near reflex is intact. Since vision is not a prerequisite for the NEAR REFLEX there are no disease entities in which the light reflex is present but the near absent.

Introduction to pupillary assessment

Normal pupils are near equal in size. Remember the normal pupil reflexes.

1. Response to a light shone into one pupil.

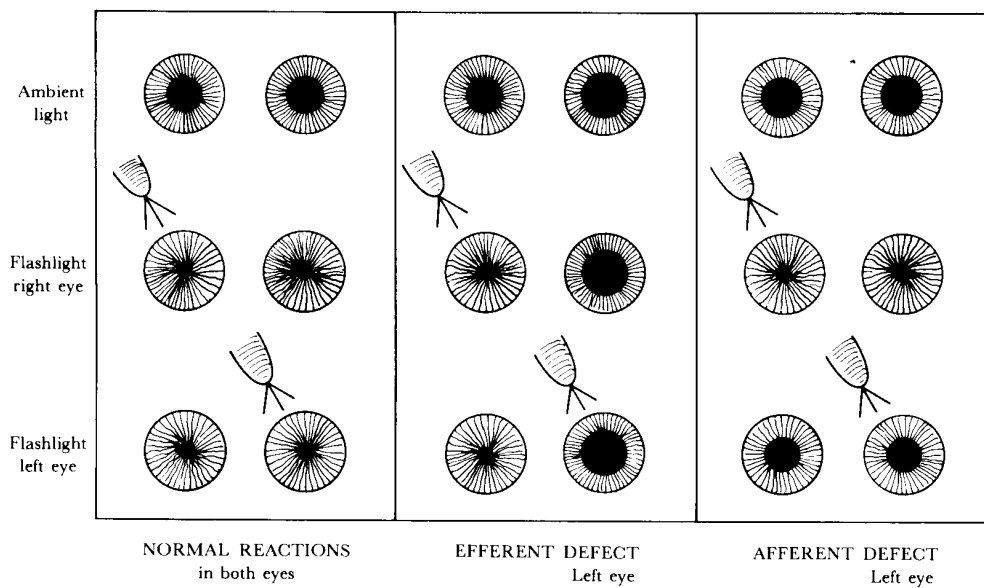
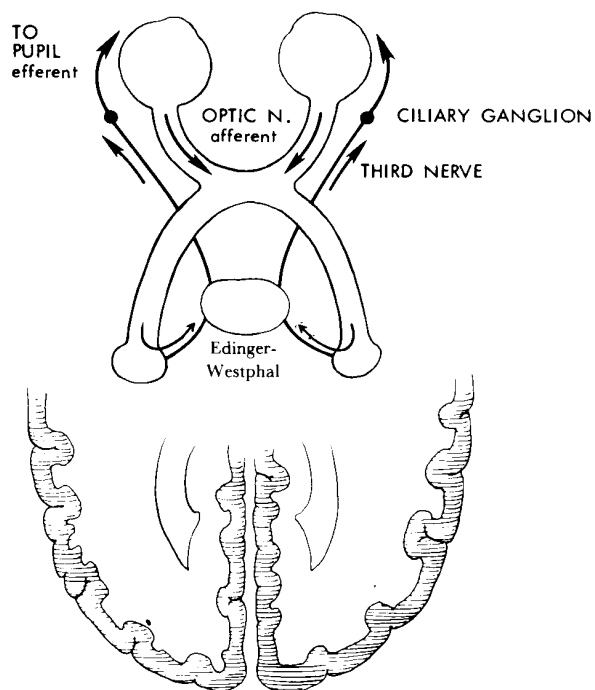
- | | | |
|------------------------|---|---|
| a. Direct response | = | pupil constriction in that eye. |
| b. Consensual response | = | Simultaneous constriction of the other pupil. |
| c. Swinging light test | = | Rapid changes of illumination from one eye to the other. Both pupils should stay equally constricted. |

2. Response to Near

Accommodation, convergence and miosis.

Practical Skills 2: Pupillary responses

PUPILLARY PATHWAYS AND REFLEXES



eg, atropine in eye
third nerve palsy

eg, optic neuritis

PRACTICAL SKILLS 2: (cont'd)

Students should consider a series of sites for lesions and predict what effect such a lesion would have on the pupil reflexes of both eyes.

a) Complete optic nerve / retinal	Total afferent pupillary defect (TAPD)
b) Incomplete optic nerve or mod severe retinal	Relative afferent pupillary defect (RAPD)
c) Central (Argyll Robertson)	bilateral, small irregular pupils, light near dissociation, difficult to dilate (syphilis)
d) Third nerve palsy	Pupil dilated, no response to light - direct or consensual. Emergency ? aneurysm.
e) Postganglionic (Holmes Adie)	Denervation of the postganglionic supply to the sphincter pupillae, possibly post-viral. Pupil large and regular (initially) Light near dissociation - light absent or very slow, near very slow / tonic, dilatation slow.

Finally consider the effect of sleep, alcohol and opiates on pupils - small as a result of decreased inhibition of the 3rd nerve nucleus. Alarm large, death and AACG fixed. NB: Students are expected to review the anatomy of Oculosympathetic palsy (Horner's Syndrome), the three neurone arc (posterior hypothalamus - cilio-spinal centre of Budge [C8-T2] - superior cervical ganglion to the dilator pupillae [via ophthalmic division of the trigeminal nve, then nasociliary and long ciliary nerves]) and causes of Horner's syndrome (Congenital, carotid aneurysm, lesions of the neck e.g. trauma or surgery, brain stem vascular disease or MS, Pancoasts tumour of the lung etc.) in their private study period. Therefore this will not be covered in this practical session)

INTRODUCTION TO VISUAL FIELD ASSESSMENT

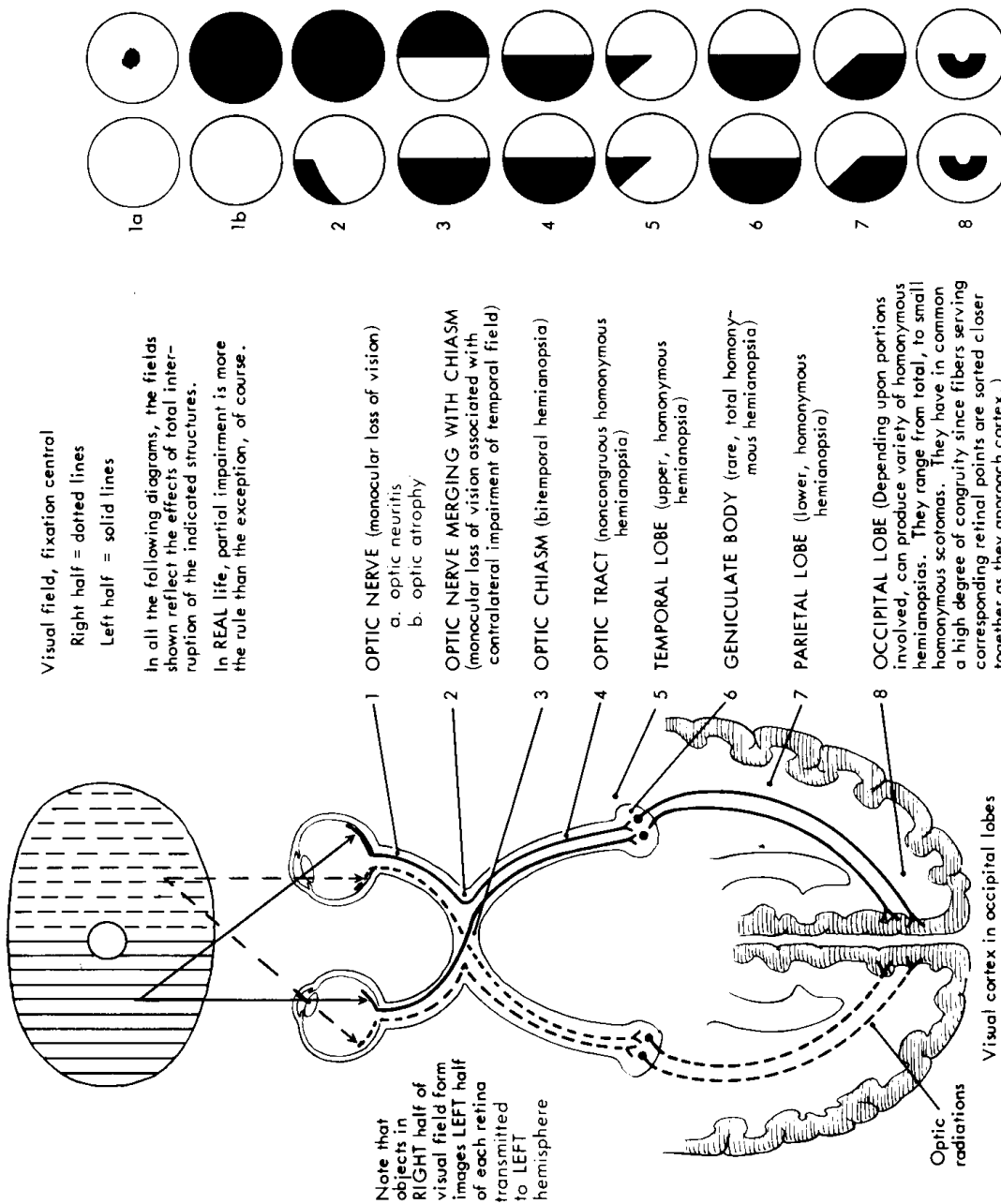
BACKGROUND:

Revise relevant anatomy: optic nerves, decussation at chiasm, optic tracts, optic radiation and occipital cortex. Understand relative preservation of spatial relationship of fibres, both horizontally, apart from decussation and vertically, e.g. lower half retinal fibres remain in lower half of pathways. Preponderance of macula fibres in centre of optic nerve. Homonymous and bitemporal defects.

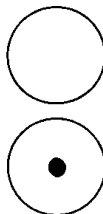VISUAL FIELD ASSESSMENT BY CONFRONTATION:

1. The examiner and subject should be seated approximately 70-100cm apart such that the hand / fingers/ target/ occupies a plane midway between them.
2. Use simultaneous presentation of hands as screen for hemianopia with both of the patients eyes open, then proceed to formal confrontation test.
3. Confrontation test using moving finger as target or counting fingers in peripheral field. The examiner should ask the subject to close one eye at a time in order to examine a single field. The subject should look at the examiners eye (left eye for field of subjects right eye and vice-versa) and the examiner should compare his/her field vision with the patient, movement of the finger or target should be made from the periphery to centre of the visual field in the shape of a diagonal cross. Emphasise the extent of the temporal field which extends to 90-100 degrees.
4. Identifying subtle central scotoma or the blind spot. This can only be done with small targets, eg. hat pin. If time allows this may be demonstrated, but this subject will be covered in "advanced visual fields" in the fourth year attachment.

VISUAL PATHWAYS WITH ASSOCIATED FIELD DEFECTS



FIELD DEFECTS ASSOCIATED WITH OCULAR PROBLEMS



Macular degeneration



Glaucoma



Retinal detachment

PRACTICAL SKILLS 3: EXTRA-OCULAR MUSCLE MOVEMENTS AND COVER TEST

Introduction

Revise the essentials. Ocular movements are performed by the 6 extraocular muscles. Each muscle moves the eye particularly in one direction (primary action) but also has other less pronounced effects (secondary actions). Movements of one eye are referred to as **ductions** (e.g. abduction, adduction), whilst movements of both eyes together are termed **versions** (e.g. laevoversion and dextroversion).

In adults and older children failure of the two eyes to move together in synchrony and maintain the visual axes parallel, results in **diplopia**. In young children with a squint, in whom the visual axes are not parallel, the brain will suppress the image from the deviating eye and hence the child will not complain of diplopia. Prolonged periods of such suppression will result in a form of **amblyopia** ("lazy eye").

Any patient with a suspected squint should be examined using the **cover test** and testing of the extraocular movements. A squint may be termed concomitant or incomitant. In **concomitant squints**, the deviation does not vary with different positions of gaze, whereas in **incomitant squints** the deviation does increase or decrease depending on which direction the eyes are looking. Incomitant squints usually result in diplopia and are due to disease of the muscles or nerve supply to the muscles.

The six extraocular muscles and their actions (noting the nerve supply) :

	Action(s)	Nerve Supply
Medial rectus	Adduction	III
Superior rectus	Elevation	III
Inferior rectus	Depression	III
Inferior oblique	Extorsion and elevation	III
Superior oblique	Intorsion and depression	IV
Lateral rectus	Abduction	VI

NB> The third cranial nerve also supplies the levator palpebrae in the upper eyelid and the parasympathetic constrictor fibres to the pupil.

EXTRA-OCULAR MUSCLE MOVEMENTS AND COVER TEST

When testing eye movements the eyes should be moved into the nine positions of gaze in order to test each of the extraocular muscles. The patient should be told to report any double vision.

The vertical recti muscles are tested when the eye is ABducted (superior rectus - elevation, inferior rectus - depression), and the oblique muscles with the eye in ADduction. Because of their insertions, when the eye is adducted the superior oblique acts purely to depress the globe and the inferior oblique to elevate it.

For those who prefer simple memory aids it might be remembered that to test the vertical actions of the inferior/superior rEcti the eye should be deviated towards the Ear, and to test the vertical actions of the inferior/superior Obliques, the eye being tested should be deviated towards the nOse.

If the patient complains of diplopia he should be asked whether the images are separated horizontally (horizontal recti paresis), vertically (vertical recti or obliques) or are just tilted (obliques). He should also be asked in which direction the separation is greatest and which image disappears on covering either eye. The image further away is derived from the eye with the paretic muscle.

The COVER-UNCOVER TEST to demonstrate strabismus (esotropia / exotropia)

This is the basic examination for the patient with a squint. Only by carrying out this test can one determine whether a patient, particularly a young child, has a squint or not. This is a **monocular test** designed to reveal a squint. Ask the patient to fix on an interesting target (e.g. picture, letter), cover one eye (non-squinting) with a hand held occluder:

- 1) In a non squinting person, when either eye is covered the other eye does not move
- 2) In a person with a **convergent squint** then the squinting eye will move from its initial (in-turning) position, in an outwards direction to take up fixation when the other eye is covered.
- 3) In a **divergent squint**, the diverging eye moves inwards to take up fixation when the non-squinting eye is covered.

Ideally this **cover test** should be performed for a target both in the **distance** (i.e. 6 metres or more) and for **near**. The near target should also have some degree of detail or pattern (i.e. not a light/ pen torch) in order to stimulate accommodation. This near examination is essential because some squints are only apparent, or are increased by accommodation, or may only occur for near (e.g. convergence excess) or for distance (e.g. intermittent exotropia).

Uncover component: when the non-squinting eye is uncovered, the strabismic eye which has temporarily taken up fixation will return to its original position ie; nasally in a convergent squint, temporally in a divergent squint.

The ALTERNATE COVER TEST to demonstrate phorias (esophoria/exophoria)

If the cover-uncover test is normal an **alternate cover test** may be performed to demonstrate an underlying phoria. In this test, both eyes are straight at the beginning and end of the procedure, one eye is covered for about 2 seconds and then quickly moved to cover the other eye. As the occluder is moved from the first eye a small compensatory movement may be identified ie. nasally in exophoria or laterally in esophoria.

The cover / uncover test should usually be used in conjunction with the **Corneal light reflection test** when attempting to identify squints.

CORNEAL LIGHT REFLECTION TEST

1. **This is a good preliminary screening test for squint**
2. Hold a pen torch in front of, and pointing towards, the child's eye from a distance of 33cm. Observe the position of the corneal light reflexes in relation to the pupils.
3. The reflexes should be in the same position in each eye i.e. symmetrical.
4. A reflex which is displaced outwards in one eye (i.e. temporally) means that the eye is turned inwards – a convergent squint.
5. A reflex which is displaced inwards (i.e. medially) in one eye means that the eye is turned outwards – a divergent squint.

APPENDIX 1: Signs & Symptoms of Eye Disease – Additional Notes

Clinical history:

It is essential to establish the nature and characteristics of the patient's complaint. The duration of and the circumstances surrounding the onset of symptoms need to be ascertained, whether the onset was gradual or sudden, unilateral or bilateral, whether the problem is intermittent, persistent or progressive, and whether there are any relieving or exacerbating factors. Any associated symptoms – ocular or systemic, should be noted. The format is as with any general medical history but with an ocular emphasis and a relevantly directed systemic review.

Presenting complaint

History of presenting complaint

Past ocular history: Squint, amblyopia, spectacles, contact lenses, trauma or surgery.

Past medical history } Direct as indicated by ocular history, e.g. a detailed vascular
Systemic enquiry } history in a patient with sudden painless loss of vision

Medications and allergies

Family history of eye or systemic disease e.g. squints, glaucoma, cataract and diabetes.

Please see Visual Loss / Acute Red Eye, and pages 10 – 11 in the recommended text (“Ophthalmology. An illustrated Colour Text.” Batterbury and Bowling.) for further reading.

Key Symptoms:

Symptom	Comments and examples
Visual loss	Is it unilateral or bilateral? For example, unilateral visual loss is likely to be ocular whereas bilateral is more likely to be a result of visual pathways or cortical involvement. Is it sudden or gradual? Does it only involve one part of the field or the complete field? Is it transient, constant or progressive? Gradual loss in one eye may be cataract whereas sudden loss suggests a vascular aetiology; transient loss may be amaurosis fugax, a premonitory sign of a CVA. Loss of the superior field in one eye may be due to occlusion of a branch of a retinal vessel or a retinal detachment. Central visual loss or distortion, with preservation of the peripheral field, may be due to age-related macular degeneration. Eliciting other symptoms may contribute to the diagnosis. For example, a history flashing lights in one eye and a shower of floaters (mobile spots in front of the eyes) a week prior to a history of visual loss may suggest retinal detachment, whereas visual loss with sudden onset of dark or red blobs suggests a vitreous haemorrhage. Accompanying headaches, temporal artery tenderness, or jaw claudication may direct the examiner to consider giant cell arteritis.
Pain	What is the character of the pain? Is it sharp or dull, intermittent or constant? A sharp pain or irritation may suggest a sub-tarsal or corneal foreign body or corneal abrasion. A deep or boring pain is more likely to suggest serious disease, as does the presence of a red eye. Is the pain exacerbated by reading, or on accommodation, as in iritis?
Redness	Unilateral or bilateral? Conjunctivitis is more likely to be bilateral and accompanied by purulent discharge, whereas iritis or acute glaucoma usually present unilaterally, but with pronounced pain. What is the distribution of the redness? Is it diffuse, mainly affecting the tarsal conjunctiva as in conjunctivitis or sectorial on the bulbar conjunctiva as in

	episcleritis or scleritis? Localisation around the cornea (circum-corneal) suggests a more serious inflammation such as keratitis (corneal inflammation) or anterior uveitis.
Photopsia	Flashes of light in one eye with onset of floaters suggest vitreous degeneration with acute detachment of the vitreous from the retina. The flashes are from traction from the vitreous and stimulation of the neurosensory retina. This can result in a hole or tear in the retina and eventually lead to a retinal detachment.
Diplopia / double vision	Is diplopia monocular (cataract, media opacities) or binocular (misalignment of the ocular axes)? Are the two images next to each other or above and below each other? Are they tilted?
Photophobia	The patient may complain of light sensitivity. This may be due to glare from cataract or because there is inflammation in the eye due to uveitis or keratitis.
Discharge	Purulent discharge suggests an infective conjunctivitis, mucous or watery discharge may suggest allergic conjunctivitis.
Epiphora and lacrimation	Increased tearing can result from any form of irritation or inflammation of the cornea. Overflow can result from increased tearing, or insufficient drainage through the naso-lacrimal system.
Itchiness	A history of hay fever or allergic eye disease may cause itchy, gritty eyes, as may blepharitis.
Grittiness and irritation	Grittiness, irritation or foreign-body sensation is usually due to an ocular surface abnormality such as a dry eye, small recurrent erosion or a foreign body.

Examination:

Having taken an appropriate history, a simple but systematic examination as outlined below will often lead you to a short-list of diagnostic possibilities. Please see Practical Skills and pages 12 – 15 in the recommended text (Ophthalmology. An Illustrated Text. Batterbury and Bowling, Churchill Livingstone) for further explanation. As many ocular disorders have systemic associations, a systemic examination may also be required.

	<u>Comment</u>
General inspection	
Vision A Snellen chart, a near reading chart and a pinhole is required.	Check near and distance vision with the patient's own spectacles. One eye at a time is tested; improvement using a pinhole suggests a correctable refractive error.
Colour vision Use a red target or Ishihara plates.	Use a red target to compare colour vision in each eye. Optic nerve disease such as optic neuritis causes the red colour to appear desaturated or washed out, compared to the normal eye. Ishihara plates are used to identify congenital colour abnormalities but may also be used in acquired colour defects.
Visual fields to confrontation A large white (and possibly red) pin is required	Sit at the same level as the patient, approximately one metre apart. Asking the patient to look at your face and see if any parts are missing can often pick up hemianopias and central scotomas. The patient's field in each eye individually is then compared with your own, using targets equidistant between you

	and the patient. Use 'finger counting' centrally and then test the peripheral field using a white target coming in from the periphery. The blind spot may be plotted using a red pin if required.
Eye movements A pen torch and an occluder are used.	The corneal reflexes should be symmetrical if the eyes are aligned. Performing a cover-uncover test on each eye will elicit a manifest squint, follow this by asking the patient to follow a target or light into the 9 (union jack) positions of gaze to see if this elicits diplopia.
Pupils Use a bright pen torch with an even beam of light.	Are the pupils mobile, round and equal in size? Is there a 'direct' and 'consensual' response? Is there a relative afferent defect on the swinging flashlight test? A lack of constriction or a relative dilatation in one pupil indicates optic nerve or extensive retinal disease. Finally check that the pupils constrict on accommodation by asking the patient to look at a near target.
Examination of the external eye – Use a pen torch or ophthalmoscope to examine systematically the lids and anterior structures of the eye.	Examine the eyelids, conjunctiva, cornea, anterior chamber and iris. Are the appearances normal? Is there redness, swelling, or discharge? What is the distribution? Is the cornea bright, shiny and clear? Are there opacities, abrasions, abnormal blood vessels or foreign bodies? Does the cornea stain with fluorescein? Is the anterior chamber deep? Does it have blood or pus cells within it? Does light shining from one side of the eye light up the whole iris? Can you see the iris details clearly- does it have dilated vessels or appear abnormal in any other way?

Dilate pupils with a drop of tropicamide 0.5% or 1.0% (onset within 20 minutes, lasts 2 to 4 hours) to examine the red reflex and posterior segment of the eye.

Red reflex Use an ophthalmoscope.	Use an ophthalmoscope to assess the eye from approximately a 1/3 rd of a metre away, dial in 'plus' lenses until the iris and then the red reflex is seen clearly. As some of the light entering the eye is reflected back by the retina, an even red glow is usually obtained. Any opacity within the normally transparent structures of the eye will cause dark obscuration of the red reflex. Cataract is the most common cause of obscuration of part or the entire red reflex.
Examination of the posterior segment. Use an ophthalmoscope.	Ask the patient to fix on a distant target then systematically examine the ocular fundus. Start with the optic nerve head; follow the vessels along the arcades into each quadrant before examining the retina between the vessels. Then finally examine the macula, which is temporal to the optic disc.

APPENDIX 2: VISION LOSS – Additional Notes

AIMS:

1. To understand and prioritise the common causes of acute visual loss
2. To understand and manage appropriately less acute forms of visual loss
3. To be acquainted with visual prognosis in order to inform patient
4. To be aware of legal definitions and restrictions related to visual loss
5. Use of support services eg. partial sight/blind registration; blind societies; low visual aid provision; guide dogs for the blind
6. To understand the impact of loss of vision in the family and community
7. Blindness prevention

Introduction to vision loss

Loss of vision involves not only the eye but also the central elements of the visual apparatus. Loss of vision can therefore be subdivided **anatomically** into three subgroups:

Anterior to chiasm

Chiasmal

Posterior to chiasm

Lesions anterior to the optic chiasm, affecting the eye or optic nerve, are likely to produce visual loss in only one eye (or one eye at a time), whereas chiasmal lesions usually lead to bitemporal field involvement and retrochiasmal lesions (posterior to the chiasm) tend to produce hemianopic field defects.

Loss of vision can also be divided **temporally** into acute visual loss and gradual visual loss. Conditions which cause acute visual loss, ie. within a few minutes to few hours, should be treated as ophthalmic emergencies.

Important aspects of history (also see lecture 2)

1. Speed of onset - acute or gradual
2. Extent of visual loss total / central / partial / hemifield
3. One eye or both eyes affected
4. Other ocular symptoms
photopsia / flashing lights / "floaters"
metamorphopsia (central distortion)
ocular pain - consider differential of acute red eye
5. Systemic symptoms
headache
Jaw claudication etc. (GCA)
6. Systemic disease
Hypertension
Diabetes
Cardiovascular disease

ACUTE LOSS OF VISION

Common causes of persisting* painless acute total/subtotal loss of vision in one eye

1. Ischaemic optic neuropathy - may be arteritic (giant cell arteritis) or non-arteritic
2. Central retinal artery occlusion or large branch retinal artery occlusion
3. Central retinal vein occlusion or large branch retinal vein occlusion

Less common but equally important acute or subacute causes of visual loss in one eye

4. Vitreous haemorrhage (trauma / retinal detachment / diabetic retinopathy)
5. Retinal detachment
6. Retrobulbar neuritis (may be associated with mild degree of pain)

Acute loss of vision affecting both eyes

1. Cerebral infarction involving optic tract, radiation or occipital cortex

***NB. Amaurosis fugax:** *by definition is a transient loss of vision in one eye lasting usually only a few minutes and at most a few hours - essentially a TIA involving the eye and usually secondary to embolic event from carotid or heart.*

Immediate management of sudden loss of vision

These conditions should all be treated as ophthalmic emergencies and the importance of excluding giant cell arteritis cannot be overstated in relation to sudden loss of vision in the contralateral eye.

Students must be familiar with the symptoms, fundal appearances, and management of all these conditions.

COMMON CAUSES OF PAINLESS GRADUAL LOSS OF VISION

1. Age related macular degeneration (ARMD)
2. Chronic open angle glaucoma (COAG)
3. Senile cataract
4. Diabetic retinopathy
5. Extreme myopia

These are very common conditions that the student/graduate will encounter in general medicine, accident and emergency, general practice etc.

Other important (but less common) causes of gradual loss of vision

1. Tobacco/alcohol (nutritional) amblyopia (usually one eye more severely affected)
2. Toxic optic neuropathies - drugs, heavy metals
3. Retinitis pigmentosa

COMMON CAUSES OF PAINLESS GRADUAL LOSS OF VISION (cont.)

Age related macular degeneration (ARMD)

This may be of very gradual onset, or if associated with sub-retinal neovascularisation and haemorrhage, may present rapidly over a few days to weeks with profound loss of central vision. Students should be aware of the difference between "dry" and "wet" macular degeneration and the progression of the disease and the use of the AMSLER grid.

ARMD is one of the most common reasons for blind registration in adulthood. The prevalence (for all degrees from minor to severe) of ARMD rises from approximately 2% in the 54-64 year old age group to almost 30% in the 75-85 year old age group.

Students should be familiar with the fundal appearances, symptoms and prognosis.

Chronic open angle glaucoma (COAG)

The association of 1. an open anterior chamber angle, 2. chronically raised intra-ocular pressure (normal 11-21mHg), 3. "cupping" of the optic disc (students should recall CDR ratios) and 4. progressive loss of visual field, characterise chronic open angle glaucoma. This is a very common disease that causes gradual progressive field loss if left untreated, it is often picked up by optometrists when patients are being examined for spectacles. It affects approximately 1% of persons between 60-70 years of age and 3% of the population over 75 years. Affected subjects may provide a family history and are usually over 40 years of age.

Students should be familiar with optic disc appearance, prognosis, medical management, and surgical management. The difference between acute closed angle glaucoma and chronic open angle glaucoma must be clearly understood.

Senile and other forms of cataract (also see lecture 9)

This is the most common cause of gradual visual impairment, short of blindness, in the elderly. Indeed, lens opacities which reduce visual acuity to 6/9 or less have a prevalence of almost 50% in subjects over 75 years of age !

Students must be aware of symptoms, signs and associations of cataract. They should also have a clear understanding of the surgical management of this condition, which they can impart to patients. Cataract extraction is the most common elective surgical procedure carried out with an annual extraction rate of greater than 1% in the over seventies.

Diabetic Retinopathy

Diabetes affects 2 to 2.5% of populations of Northern European extraction but may affect 4 to 8% of Maori and Pacific Islanders. There is an approximate 8:1 ratio between NIDDM and insulin dependent cases. Poor control and duration of diabetes are associated with greater risk of diabetic retinopathy. Diabetic retinopathy remains one of the most common causes of blind registration in the NZ.

Students should be familiar with the classification of diabetic retinopathy

Extreme Myopia

Myopia of greater than -8.0 to -10.0 Dioptres is frequently associated with a number of degenerative ocular conditions which may lead to severe visual impairment including: myopic macular degeneration; chronic open angle glaucoma; cataract; and retinal detachment.

DEFINING VISUAL IMPAIRMENT

Students must familiarise themselves with the following during the fifth year course:

- a) Range of “normal” visual acuity and refractive error
- b) Blindness registration/partial sight registration
- c) Legal requirements to drive
- d) Local services for the visually impaired
- e) The role of low visual aids

RELEVANCE TO OTHER CURRICULUM THEMES

Visual loss is directly related to many other components of the medical curriculum. Students should review the anatomy of the visual pathways and cerebral/ocular blood supply. Visual loss may be associated with common medical disorders including diabetes, hypertension and cardiovascular disease. Since visual loss of gradual onset primarily affects the elderly there are obvious ramifications in relation to medicine in the community and maintaining independence in the ageing population. Disease prevention by early identification and appropriate management of early diabetic retinopathy or early glaucoma is important. Since visual loss involves not only the eye but also the central visual apparatus there is a significant degree of overlap with neurology themes.

APPENDIX 3: CARE OF THE VISUALLY DISABLED

In every doctor's practice, they will from time to time come across visually disabled persons. During your clinical attachment, you will visit the Auckland Eye Department Vision assessment Clinic (VAC). This is for people with low vision and it also supplies an electrodiagnostic, rehabilitation, optometric and genetic service. The following are some notes about visual impairment.

**ASSESSMENT OF: VISUAL IMPAIRMENT
 VISUAL DISABILITY
 VISUAL HANDICAP**

VISION ASSESSMENT CLINIC (Auckland Hospital)

Multidisciplinary, tertiary care clinic, designed to assist patients who have already been assessed by an Ophthalmologist. Referrals are accepted from GPs, Optometrists and Social Workers of RNZFB.

Ophthalmologist:

Specialising in medical retinal disorders, electrodiagnostic studies

Optometrist:

Experienced in assessing and dispensing optical and electronic Low Vision Aids for the visually impaired

Visual rehabilitation Coordinator:

Experienced in rehabilitation of the visually impaired.

Technical Assistant / Orthoptist:

Technician for visual field and colour vision testing. Electrodiagnostic technician

Rehabilitation Instructor from the RNZFB:

Rehabilitation of the visually impaired, including home visits.

Clinical Geneticist:

Genetic counselling for families with inherited ophthalmic disorders.

Measurement of VISUAL IMPAIRMENT

	Moderate	Severe	Profound
<u>Visual Acuity</u>	6/18 – 6/36	6/36 – 3/60	< 2/60

Other factors modifying the degree of visual impairment:

1. Visual Field
 - Central stroma
 - Very restricted field
 - Patchy visual field
 - Hemianopia – homonymous / bitemporal
2. Contrast sensitivity
 - Affected by diabetic retinopathy, cataracts and other conditions
3. Colour Vision
4. Night Vision
 - e.g. Retinitis Pigmentosa
5. Fluctuating Vision
 - Temporary reductions in vision secondary to: vitreous hge / macular oedema / diabetics with fluctuations in blood glucose / temporary e.g. awaiting cataract surgery.

Optical Aids For VISUAL DISABILITY

Moderate: Optical appliances for detailed visual tasks
→ NEAR NORMAL vision with aids e.g. low magnification magnifiers

Severe: Optical appliances for detailed visual tasks
→ LESS THAN NORMAL vision with aids e.g. higher magnification magnifiers (but higher magnification gives a smaller field)

A realistic goal is reading for information not reading for pleasure.

Profound: Optical appliances and OTHER SKILLS for visual tasks e.g. closed circuit TV or other high tech aids.

Aids for Daily Living (ADL) for Visual Handicap

Moderate: Meet MOST social expectations visually

Severe: Meet MANY social expectations visually

Profound: Difficulty with many social expectations

Aids for Daily Living (ADL) for Moderate / Severe:

Extra lighting, large print, felt-tip pens, Typoscope (reduces glare), heavy lined paper.

Use of contrast e.g. white cup with coffee / black with milk

Large print cards, black watch face with white print

Maxiphone.

ADL for Profound: TACTILE

Elastic lined writing frame, tape measure with tactile markings, self-threading needles, cheque templates, Braille playing cards, talking clock.

Factors modifying the degree of visual handicap:

Current age, age of onset, social expectations

Social support (family / community)

Psychological adjustment to visual impairment

Self-image (i.e. solitary / extrovert/ organised/ preconceived idea of "blind person")

Physical health

Occupation

Royal New Zealand Foundation for the Blind (RNZFB)

Registration Criteria:

Full - Visual acuity (VA) not exceeding 6/60 or visual field not wider than 20 degrees.

Restricted - VA 6/24 to 6/60

Temporary- e.g. awaiting eye surgery

RNZFB Services

Visual Impairment	Moderate	Severe	Profound
1. Social support groups Sport / craft/ cultural (e.g. Ngati Kapo) / youth groups	+	++	+++
2. Vocational assistance	modify	—————→ new technology	
3. Daily living skills O & M	advice	instruction	home visit / intense rehab
4. Talking books	-	+	++
5. Guide Dog	-	-	+
6. Counselling, Field Workers, Child and Family counsellors, Whanau workers	+	+	++

Community Services

Financial Assistance:

1. Disability allowance

Provides for extra expenses incurred because of disability (Means tested) - \$40/week

2. Blind Invalid Benefit

Not means tested (<2/60 and <3 degree visual field)

3. Equipment Funding

Assistance through income support service for education, training and employment. Not means tested. Equipment recommended by DSW accredited assessor.

4. Diabetic Educators

Educational sessions. Organise motivational support groups. Advice on modified equipment e.g. blood monitors and click syringes.

Other Community Services

1. "60's plus"

The over 60's are entitled to help from "60's plus". This includes housework, shopping and transport. Obtained through extramural.

2. Domiciliary Occupational Therapist.

Provide safety aids e.g. rails, non-slip surfaces. The combination of visual impairment and physical problems can compound to make a person less secure in their home environment.

3. Social Interaction Groups.

Run by the community e.g. Care and Craft

- a place to go and meet people
- gives relief to care givers
- helps establish social contact and reduces the sense of being cut off through being homebound and not seeing peoples' faces.



The Department of Ophthalmology

4th floor, Building 504

Faculty of Medical and Health Sciences

The University of Auckland

www.fmhs.auckland.ac.nz/som/ophthalmology